

## Abdominal Injuries

### Introduction

Changing patterns of warfare coupled with improvements in protective body armor have combined synergistically to decrease truncal and abdominal trauma in contrast to previous conflicts. Despite the many advances in protective body armor, penetrating abdominal trauma remains an inevitable component of war surgery. Rapid recognition and treatment of intraabdominal injuries are necessary to ensure maximal survival with the minimum amount of morbidity.

Trauma to the abdomen, both blunt and penetrating, can lead to occult injury that can be devastating or fatal if not recognized and treated in a timely manner. In an unstable patient who presents with an abdominal injury, the decision to operate is usually straightforward. In this circumstance, exploratory laparotomy should be performed as soon as the diagnosis is made. In a few rapidly hemorrhaging patients with thoracoabdominal injuries, a rapid decision must be made as to which cavity to enter first. This chapter addresses some of these issues.

**Penetrating injuries below the nipples, above the symphysis pubis, and between the posterior axillary lines must be treated as injuries to the abdomen and mandate further workup and/or exploratory laparotomy.**

- Posterior truncal penetrating injuries from the tip of the scapula to the sacrum may also cause retroperitoneal and/or intraabdominal injuries. A low threshold for exploratory laparotomy in these patients is warranted when limited diagnostic modalities are available.

### **Diagnosis of Abdominal Injury**

- Document a focused history to include time of injury, mechanism of injury, previous treatments employed, and any drugs administered.
- Inspection of the fully exposed chest and abdomen will be the most reliable part of the physical examination, especially regarding penetrating injuries.
- The most important determination is whether or not a patient requires urgent laparotomy. Do not focus on making a specific diagnosis.

### **Indications for Laparotomy**

The most important decision is to determine **who** needs surgery.

- Patients **who** mandate expeditious abdominal exploration are patients with the following signs and symptoms:
  - Physiological instability on presentation with an obvious penetrating abdominal injury.
  - Penetrating abdominal wounds in the zones as described in the zone of injury explained above when no means to exclude an intraabdominal injury are available.
  - Present with other penetrating truncal injuries with potential for peritoneal penetration and clinical signs/symptoms of intraperitoneal injury.
  - Present in shock with potential for blunt abdominal injuries.
- When aeromedical evacuation is uncertain and will involve substantial distance, unstable patients with life- or limb-threatening circumstances should undergo laparotomy at the nearest facility that can provide surgical care.
- Laparotomy may be delayed if necessary, depending on the operational situation. These circumstances can be generally managed by the following guidelines:
  - Stable patients with intraperitoneal injury and no signs of shock can be managed nonoperatively for several hours.
  - Initiate resuscitation.
  - Start broad-spectrum antibiotics.
  - Arrange for transport as soon as possible to the next higher role of care.

**When the tactical situation permits, aeromedical evacuation is effective, and the distance between Role 2 (Forward Surgical Team) and Role 3 (Combat Support Hospital) or higher level hospitals is short, all critically ill casualties should be medically regulated to the higher role when possible.**

### **Diagnostic Adjuncts**

Nonoperative adjuncts to diagnosing intraabdominal injuries—such as CT scan, ultrasound (US), and diagnostic peritoneal aspiration (DPA)—have been used to decrease the negative laparotomy rate in stable patients with blunt abdominal trauma. Some of the aforementioned modalities have been used in lieu of laparotomy to evaluate patients with penetrating injuries when the clinical suspicion is low for an intraabdominal injury. The practice of nonoperative management of penetrating abdominal trauma and reliance on diagnostic modalities to rule out intraabdominal injury have the potential of missing injuries, particularly in the resource-constrained environment with limited diagnostic modalities. The use of CT, DPA, and US in penetrating abdominal trauma should be reserved for stable patients with a mechanism of injury suggesting intraabdominal injury, but who lack obvious operative indication. These diagnostic modalities should be relied on only when good follow-up is possible and patients will not require long transports where rapid surgical intervention is not possible. US and DPA have some utility in unstable patients to help guide which cavity, thoracic or abdominal, should be entered first when planning operative strategy. US and DPA may also serve as triage tools in the mass casualty situation.

### **Focused Abdominal Sonography for Trauma (FAST)**

- Has become an extension of the physical examination of the abdomen, and should be performed whenever indicated and available in the setting of an abdominal injury.
- SonoSite is the current standard US military device used.
  - A 3.5–5 MHz curved probe is optimal.
  - The abdomen is examined through four standard sonographic windows: right upper quadrant, subxiphoid, left upper quadrant, and suprapubic.

**Advantages:**

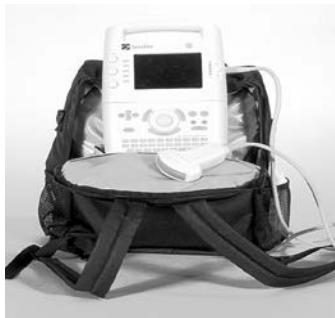- Noninvasive, may repeat frequently, quick, easy, identifies fluid in the abdomen reliably.
- Aids in prioritization of penetrating injury patients for the OR.
- Helps identify which cavity to open first in patients with thoracoabdominal injuries.
- Identifies pericardial fluid and may assist in the diagnosis of hemopneumothorax.

**Disadvantages:**

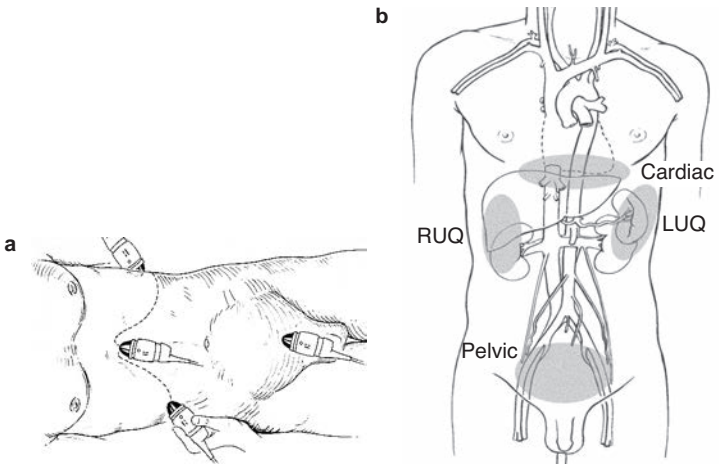
- Operator-dependent, may miss small amounts of fluid and hollow viscus injuries.
- Assists the surgeon in determining the need for laparotomy in patients with blunt abdominal injury, but does little to identify specific injuries.
- **DOES NOT** identify or stage solid organ or hollow viscus injury.

**FAST Views**

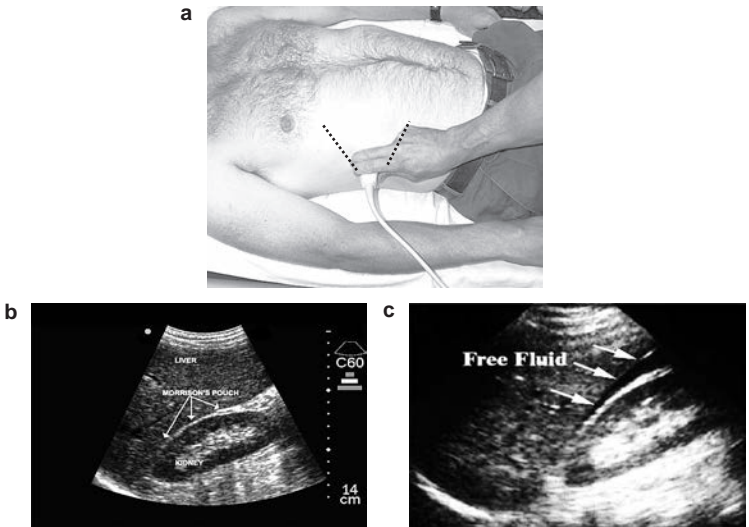
A typical portable sonography device is shown in Fig. 17-1. The standard locations for “sonographic windows” are shown in Fig. 17-2. Examples of positive and negative sonographic examinations are shown in Figs. 17-3 through 17-6.



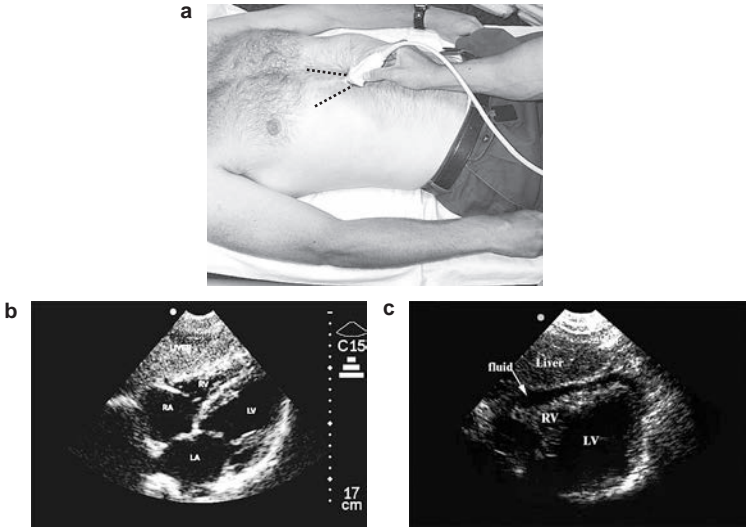
**Fig. 17-1.** Typical sonography device.  
Courtesy of SonoSite, Inc, Bothell, WA.



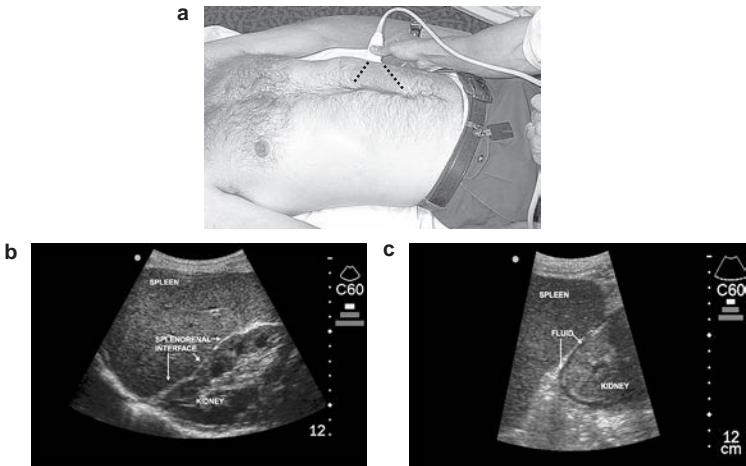
**Fig. 17-2.** The standard four locations for sonographic windows. (a) Subxiphoid. (b) Suprapubic. LUQ: left upper quadrant; RUQ: right upper quadrant.



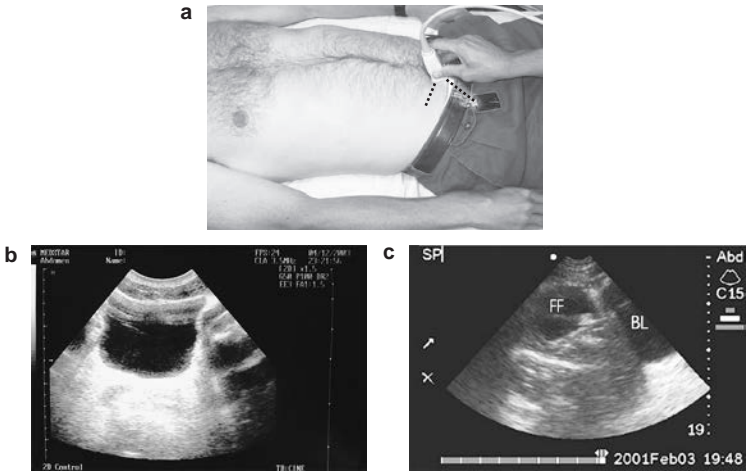
**Fig. 17-3.** (a) Right upper quadrant. (b) Normal and (c) abnormal negative sonographic examinations for the right upper quadrant.



**Fig. 17-4.** (a) Subxiphoid. (b) Normal and (c) abnormal negative sonographic examinations for the cardiac window. LA: left atrium; LV: left ventricle; RA: right atrium; RV: right ventricle.



**Fig. 17-5.** (a) Left upper quadrant. (b) Normal and (c) abnormal negative sonographic examinations for the left upper quadrant.



**Fig. 17-6.** (a) Suprapubic. (b) Normal and (c) abnormal negative sonographic examinations for the pelvic window. Abd: abdomen; BL: bladder. FF: free fluid.

### Diagnostic Peritoneal Aspiration

Historically, diagnostic peritoneal lavage played a role in blunt abdominal trauma diagnosis; however, the utility of the lavage continues to decrease in the setting of improvements in both US skills and technology, coupled with the widespread use of CT scan. Far-forward combat medical units are not routinely outfitted with appropriate equipment, such as microscopic and laboratory functions that provide cell counts or fluid enzyme determinations. Thus, the only reliable information obtained from a lavage is the aspiration of gross blood or DPA.

#### Advantages:

- Quickly ascertain intraperitoneal blood.
- May help determine which body cavity to enter first in an unstable patient with truncal injury.

#### Disadvantages:

- Invasive, often not reproducible, significantly slower than FAST.
- May be useful when US and/or CT are not available, or as triage tool.

- The following represent positive DPA:
  - Aspiration of 10 cc of gross blood.
  - Aspiration of enteric contents.
- DPA is **NOT** recommended for penetrating abdominal trauma.
- Basic technique:
  - Open technique using a small, vertical infraumbilical incision and any tubing (IV, Foley, straight, or balloon catheter).
  - Aspirate peritoneum.

## **CT Scan**

### **Advantages:**

- Defines injured anatomy in **stable** patients and provides a modality that may prevent unnecessary laparotomy in appropriately selected patients.
- When available and in **STABLE** patients, CT scan may be useful for:
  - The workup of penetrating abdominal injuries where there is a question of whether or not the projectile traversed the peritoneal cavity.
  - The evaluation of isolated penetrating retroperitoneal and posterior injuries.
- When using CT scan to evaluate penetrating retroperitoneal injuries, triple-contrast CT scan (oral, IV, and rectal) remains important to rule out injuries.

### **Disadvantages:**

- Slow.
- Requires contrast use and equipment availability.
- May miss small hollow organ injury.
- Requires transport away from the resuscitation area.
- Operator-/interpreter-dependent.

There is **NO ROLE** for CT scan in the evaluation of an **unstable** patient with obvious abdominal trauma, regardless of the mechanism of injury.



### **Wound Exploration**

- Blast injuries and improvised explosive devices create many fragments that may penetrate the skin, but not the abdominal cavity. Operative local wound exploration in the stable patient with a normal or equivocal examination may help determine the need for formal exploratory laparotomy.
- When possible, wound exploration should be performed in the OR with adequate instruments and lighting.
- Finding of an isolated fragment in the abdominal wall superficial to the anterior fascia may obviate the need for formal laparotomy.
- If there is any doubt that the fragment penetrated the abdominal cavity (eg, the tract of the projectile is not adequately identified or the fragment cannot be seen on plain film radiograph), formal laparotomy should be performed.
- CT scan, when available and used as an adjunct to wound exploration, may also be helpful in determining the trajectory of fragments and help plan wound exploration.

### **Operative Planning and Exposure Techniques**

- Administer broad-spectrum IV antibiotic prior to surgery and continue for 24 hours.
  - Redose short half-life antibiotics intraoperatively and consider redosing antibiotics with large amounts of blood loss.
- Laparotomy should be performed through a midline incision.
  - When wide exposure is needed, extend the incision superiorly just lateral to the xiphoid process and inferior to the symphysis pubis.
- Quickly pack all four quadrants with lap sponges while looking for obvious injuries.
- Control hemorrhage with packing or clamping of bleeding vessels.
- **Once packed and hemorrhage controlled, assess physiological status.**
  - Considering casualty physiology, your current resources, and location, create an operative plan to control hemorrhage, contamination, and truncate the operation if necessary.

- Attempt to limit initial exploratory laparotomy to <60 minutes.
- **ALWAYS** consider damage control principles throughout the procedure (see Chapter 12, Damage Control Surgery).
- If the patient is stable, consider definitive surgery. In general, definitive surgical procedures should be limited to procedures once the patient has been resuscitated and at a level of care with the greatest diagnostic and therapeutic resources available for patient care (ie, Role 3 facility).
- Identify all solid organ and hollow viscus injuries.
- Eviscerate the small bowel to increase workspace, if needed.
  - If needed, divide both the left and right triangular ligamentous attachments of the liver to improve exposure in the right upper quadrant or upper midline.
- Fold the left lateral segment of the liver down and to the right to improve exposure at the gastroesophageal junction.
- Improve exposure to the liver by extending the incision into the inferior sternum and/or across into the lower right chest (thoracoabdominal).

### **Gastric Injuries**

- The stomach is a vascular organ and will do well after most any repair.
- The entire stomach must be visualized.
  - When exploring the stomach, enter the lesser sac by dividing the gastrocolic ligament and reflecting the stomach up toward the head to evaluate for posterior wall injuries.
- Encircle the distal esophagus with a Penrose drain to provide traction and improve visibility for high midline injuries.
- Once all gastric injuries have been identified, minimally debride and primarily close stomach defects in 1 or 2 layers with permanent sutures.
- Place the nasogastric tube and confirm position with palpation.
  - Consider use of a large gastrostomy tube (a large Foley or Malecot may work if no gastrostomy tubes are available).
  - Remember to have the nasogastric tube or gastrostomy tube irrigate postoperatively with 30 mL of saline every 2 hours to ensure that the tube does not become clogged.

## Duodenal Injuries

Injuries to the duodenum are typically associated with massive upper abdominal trauma. Thus, early consideration for damage control surgery should be considered (see Chapter 12, Damage Control Surgery).

- Missed injuries of the duodenum have devastating morbidity.
- Bile staining or hematoma in the periduodenal tissues mandates full exploration of the duodenum (Kocher maneuver).
- Minor injuries can be primarily repaired in two layers and closed-suction drains (JP [Jackson-Pratt] drains) placed around the repair.
- Major injuries should be primarily repaired if they do not involve the ampulla, and luminal diameter will not be narrowed by >50%.
- Options for closing injuries of >50%:
  - Close duodenal wall around a tube duodenostomy.
    - ◆ Use a no. 2-0 absorbable suture (VICRYL).
    - ◆ Use the largest Malecot catheter or drainage tube available.
- Perform a pyloric exclusion procedure.
  - Through a gastrotomy, ligate the pylorus with an absorbable suture or by using a noncutting TA stapling device. Staple but **do not divide** the pylorus.
  - Close the duodenal injury.
  - Create a gastrojejunostomy anastomosis between the jejeunal limb and the gastrotomy (Fig. 17-7).
  - Remember to place a feeding jejunostomy for nutrition.
  - The procedure of **LAST RESORT** is pancreaticoduodenectomy. In the acute and damage control settings, there is NO role for reconstruction during the initial procedure in patients with traumatic pancreaticoduodenectomy.
- Duodenal injury caveats.
  - Widely drain all injuries with closed-suction drains.
  - Any method used to close the pylorus will typically last only 14–21 days.
  - The possibility of injury to the biliary and pancreatic ducts should be considered when injuries involve the second portion of the duodenum or the pancreatic head.

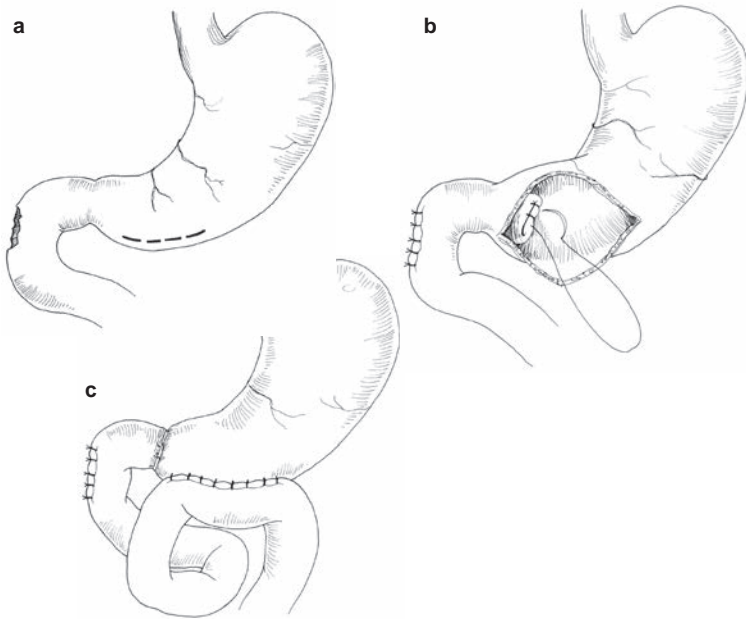


Fig. 17-7. (a) Pyloric exclusion. (b) Duodenal injury repair. (c) Gastrojejunostomy.

### Pancreatic Injuries

- Any injury to the pancreas/duct requires drainage.
- Even if ductal injury is not identified, it should be presumed and drained with **multiple** closed-suction drains.
  - Resect clearly nonviable pancreatic body/tail tissue.

Major injuries to the head of the pancreas may require pancreaticoduodenectomy. If pancreaticoduodenectomy is performed as part of damage control surgery, reconstruction should be delayed until the patient has been resuscitated. Consideration for reconstruction should be given if definitive surgery will take more than 72 hours from time of injury. If reconstruction is not possible, then wide drainage with multiple closed-suction drains should be used and the patient's abdomen left open to facilitate reconstruction.

- Transection or near-transection of the pancreatic duct can be treated by:
  - Drainage.
  - Distal pancreatectomy (typically requires splenectomy).

### **Liver Injuries**

- Most liver injuries can be successfully treated with direct pressure and/or packing, followed by aggressive resuscitation and correction of coagulopathy.
- If packing is not successful, generous exposure is required and should be gained early and aggressively.
  - Mobilize triangular, falciform, and coronary ligaments for full exposure.
  - Use extension into the pericardium and/or right chest, if needed.
  - Place several laparotomy pads above the dome of the liver to displace it down into the field of view.
- Short duration clamping of the hepatic artery and portal vein (Pringle maneuver) may be required to slow bleeding while gaining other control.
- If bleeding continues despite the Pringle maneuver, especially from behind the liver, this indicates a retrohepatic venous injury or a retrohepatic vena caval injury. These injuries carry an extremely high mortality. If the retrohepatic hemorrhage is controlled with packing, the best mechanism to deal with these injuries is to maintain tamponade by aggressively packing the liver and ICU resuscitation. If necessary, these injuries may be addressed once the patient has been more adequately resuscitated and transferred to a higher level of care with the resources to care for the patient.
- As a last resort, consider cross-clamping the aorta in the left chest or upper abdomen if all other modalities fail to control hemorrhage to the liver.
- Use finger fracture of liver parenchyma to expose deep bleeding vessels and oversew directly.
- Large exposed injuries of the liver parenchyma can be controlled in a number of ways:
  - Exposed large vessels and ducts should be suture-ligated.

- Overlapping mattress sutures of no. 0 chromic on a blunt liver needle is fast and effective for controlling raw surface bleeding.
- Placement of SURGICEL on the raw surface and high-power electrocautery is also effective.
- Bleeding tracts through the liver can be controlled by tying off the end of a Penrose drain, placing it through the tract, and “inflating” it with saline to tamponade the tract.
- Urgent surgical resection is **strongly discouraged**:
  - Indicated only when packing/pressure fails.
  - Follow functional or injury pattern, not anatomical lines.
- Use a pedicle of omentum in a large defect to reduce dead space.

**Prevention and treatment of coagulopathy, hypothermia, and acidosis are essential in the successful management of major liver injuries. APPLY DAMAGE CONTROL TECHNIQUES EARLY.**

- Retrohepatic vena cava and hepatic vein injuries require a tremendous amount of resources (blood products, operating room time, equipment) typically unavailable in a forward surgery setting (on-table triage in mass casualty).
  - Packing is the most successful option.
  - If packing fails, consider hemorrhage control by total hepatic vascular isolation or atriocaval shunt (Fig. 17-8) in order to effect injury repair.
- Provide generous closed-suction drainage around major liver injuries.

### **Biliary Tract Injuries**

- Injuries to the gallbladder are treated by cholecystectomy.
- Repair common bile duct injuries over a T-tube.
  - A no. 4-0 or smaller absorbable suture is used on the biliary tree.
- Extensive segmental loss requires choledochoenterostomy or tube choledochostomy (depending on time and patient physiology).
- Drain widely.

### Splenic Injuries

- Intraoperative splenic salvage has **NO ROLE** in combat surgery.
- Empiric left subphrenic drains should not be routinely placed postsplenectomy if the pancreas is uninvolved in the injury.
- Splenic injury should prompt exploration for associated diaphragm, stomach, pancreatic, and renal injuries.
- Theater clinical practice guidelines exist to help guide protocols for postsplenectomy immunization. All postsplenectomy patients should be immunized with pneumococcal, hemophilus, and meningococcal vaccine.

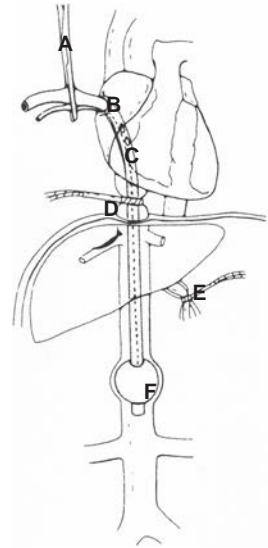
### Small Bowel Injuries

- Basic tenets:
  - Debride wound edges to freshly bleeding tissue.
  - Close enterotomies in 1 or 2 layers (skin stapler is a rapid alternative for damage control).
- With multiple enterotomies to one segment of <50% of small bowel length, perform single resection with primary anastomosis. Avoid multiple resections.

### Colon Injuries

Simple, isolated colon injuries are uncommon. In indigenous populations and enemy combatants (eg, patients who cannot be readily evacuated), diversion with colostomy should be the procedure of choice.

- Simple, isolated colon (nonrectal) injuries should be repaired primarily.
  - Debride wound edges to normal, noncontused tissue.
  - Perform two-layer closure or anastomosis.



**Fig. 17-8.** Atriacaval shunt. (A) Proximal clamp occlusion; (B) purse-string suture, right atrium; (C) fenestrations made in tube; (D) suprahepatic inferior vena cava control; (E) Pringle maneuver; and (F) endotracheal tube, balloon inflated above renal veins.

- For **complex injuries, strongly consider damage control followed by colostomy/diversion**, especially when associated with:
  - Massive blood transfusion requirement.
  - Ongoing hypotension.
  - Hypoxia (severe pulmonary injury).
  - Reperfusion injury (vascular injury).
  - Multiple other injuries.
  - High-velocity injuries.
  - Extensive local tissue damage.
  - Distal colon (ie, distal sigmoid and rectal) injuries should be resected and ostomy formed due to the high incidence of leak from anastomosis.
- Potential breakdown of a repair or anastomosis is high in the setting of concomitant pancreatic injury.
- Damage control technique for colon injury:
  - Control contamination with ligation/stapling of bowel.
  - Resuscitation in the ICU.
  - Creation of a stoma during the definitive reconstruction.
  - Intestinal continuity should be restored or ostomy performed within 72 hours of original damage control procedure.
- Clearly document treatment for optimal followup throughout roles of care.
- At the time of formation, a colostomy should be matured.

### **Rectal Injuries**

Rectal injuries can be difficult to diagnose unless very dramatic. Any question of an injury raised by proximity of another injury, rectal examination, or plain abdominal film radiography **MANDATES** proctoscopy. Gentle distal washout with dilute Betadine solution may be required to be able to perform rigid proctoscopy.

- Findings can be dramatic disruptions of the rectal wall, but more commonly are subtle punctuate hemorrhages of the mucosa. All abnormal findings should prompt corrective intervention.
  - **D**iversion, **D**ebriement, **D**istal washout, and **D**rainage (the 4 D's of rectal injury). Diversion is the most important aspect of rectal injury management.



- ◆ Transabdominal sigmoid colostomy is easiest.
- ◆ If the injury has not violated the peritoneum, exploration of the extraperitoneal rectum should NOT be done at laparotomy unless indicated for an associated nonbowel injury. This avoids contaminating the abdominal cavity with stool.
- Debridement and closure of small- to medium-sized rectal wounds are unnecessary in patients who have been diverted and drained.
- Distal washout may be necessary to assess the injury. Use gentle pressure when irrigating to minimize contamination of the perirectal space.
- Routine use of presacral drains is discouraged unless gross contamination and infection are present at the time of surgery. The creation of a space to place drains should be avoided.
  - ◆ If needed, presacral drains are placed through the perineum into the retrorectal space (Fig. 17-9).

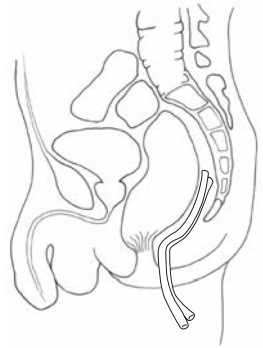


Fig. 17-9. Presacral drain.

- Peritonealized rectal injuries are easily accessed transabdominally and should be repaired and protected with diversion.

### Retroperitoneal Injuries

- Left medial visceral rotation moves the colon, pancreas, and small bowel to expose the aorta rapidly. Proximal aortic control can be rapidly obtained with compression or a clamp on the aorta at the esophageal hiatus, or through the left chest.
- Right medial visceral rotation (colon + Kocher maneuver to elevate duodenum) exposes the subhepatic vena cava.
- Three zones of the retroperitoneum (Fig. 17-10):
  - **Zone I—central, supracolic:** explore for all injuries.
  - **Zone II—lateral:** blunt trauma, avoid exploration if possible because exploration increases the likelihood of opening a stable hematoma and, thus, precipitating nephrectomy. **Explore for penetrating trauma.**

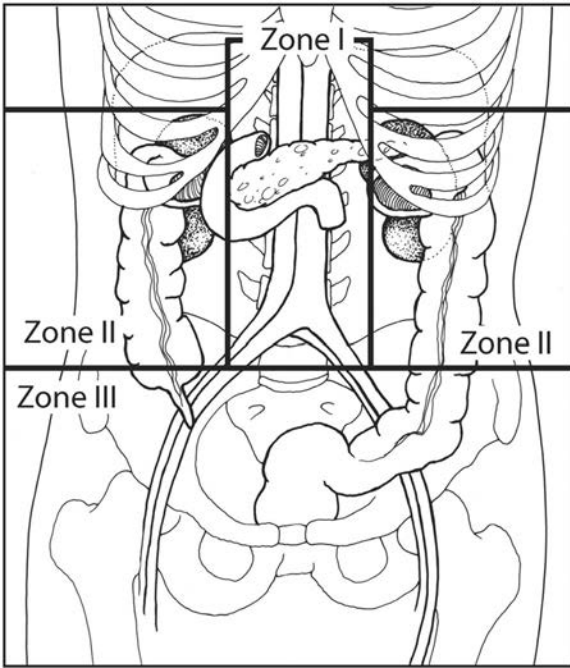


Fig. 17-10. Three zones of the retroperitoneum.

- **Zone III—pelvic:** blunt trauma, do not explore, likely associated with pelvic fracture. **Explore for penetrating trauma.**
- Gain proximal vascular control before entering the hematoma.

### Abdominal Closure

- Massive swelling associated with large amounts of blood loss and resuscitation and large injuries may necessitate temporary closures (see Chapter 12, Damage Control Surgery).
  - Avoid closing the fascia under the following circumstances:
    - ◆ Further abdominal procedures are anticipated.
    - ◆ Enteric viscera left in discontinuity.
    - ◆ Damage control laparotomy.

- A few penetrating battlefield wounds are isolated, small, and without visceral contamination, and it is perhaps safe to close the skin. **Most are not, and these patients will be passed quickly from one surgeon to the next, so the risk of missed and catastrophic infection is increased; the skin should not be closed.**
- Retention sutures should be considered, but should be reserved for patients undergoing definitive surgical repair. There is no role for the placement of retention sutures if a patient is going to return to the OR for scheduled repeat laparotomy.

For Clinical Practice Guidelines, go to  
[http://usaisr.amedd.army.mil/clinical\\_practice\\_guidelines.html](http://usaisr.amedd.army.mil/clinical_practice_guidelines.html)

