

Injuries to the Hands and Feet

Introduction

Combat injuries to the hands and feet differ from those of the arms and legs in terms of mortality and morbidity. The hands and feet have an important commonality: an intricate combination of many small structures that must function smoothly together. Because these terminal appendages are extremely specialized and represent the interface of the person to the outside world, a minor wound—causing no lasting impairment if inflicted, for example, on the thigh—can result in life-long disability when it occurs on a hand or foot.

Types of Injury

- Nonbattle injuries resulting in laceration, contusion or sprain of the hand or foot, and crush injuries involving either the hands or feet from heavy equipment are common. Such crush injuries may result in compartment syndrome.
- Missile, blast, and high-energy ordnance injuries involving the hands and feet are common in combat and may result in mutilating injuries with a permanent loss of function, innervation, or distal extremity tissue (amputation).

The Hand

Even apparently minor wounds distal to the wrist crease may violate tendon sheaths and joints, resulting in a serious deep space infection. Such wounds require a high index of suspicion for injury and a low threshold for operative exploration.

Evaluation and Initial Management

- The casualty's upper extremities should be exposed.
- Rings, watches, and other potentially constrictive material must be removed immediately.
- A preliminary neurological examination should be performed and documented.
- Vascular status of the hand should include an assessment of radial and ulnar pulses, and perfusion to each fingertip as assessed by color, warmth, and capillary refill.

Treatment of Hand Compartment Syndrome

- The hand has 10 separate fascial compartments (4 dorsal interossei, 3 palmar interossei, the thenar muscles, the hypothenar muscles, and the adductor pollicis; Fig. 24-1).

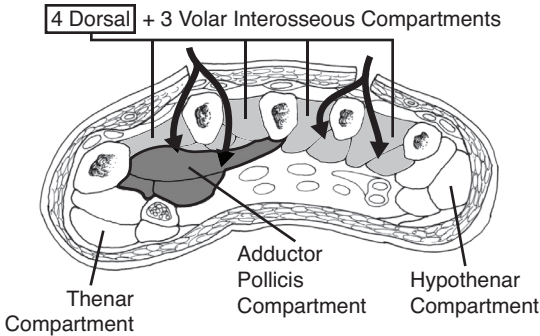


Fig. 24-1. Compartments of the hand.

- A complete hand fasciotomy consists of four incisions (shown in Fig. 24-2):
 - ◆ The **first incision** is placed along the thumb metacarpal at the radial aspect of the hand to release the fascia of the thenar muscles.
 - ◆ The **second incision** is centered dorsally on the index metacarpal. On the radial side of this bone, the fascia of the first dorsal interosseous and the adductor pollicis are incised. On the ulnar side of this bone, the fascia of the dorsal and palmar interossei is incised.

- ◆ The **third incision** is centered dorsally on the ring metacarpal. From this wound, the fascia of the dorsal and palmar interossei is released on both sides of this bone.
- ◆ The **fourth incision** is placed along the small metacarpal on the ulnar aspect of the hand to release the fascia of the hypothenar muscles.
- Although compartments are not well defined in the fingers, fingers that are severely swollen may require release of dermal and fascial constriction; care should be taken to place the skin incision away from the neurovascular bundles (Fig. 24-3).

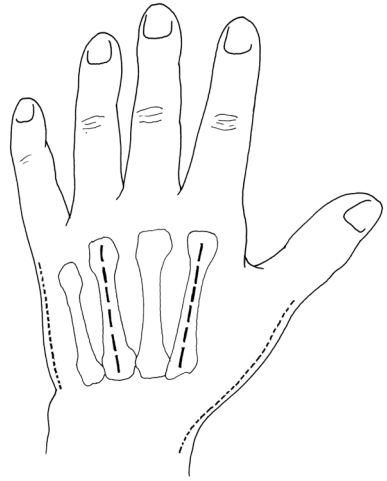


Fig. 24-2. Hand fasciotomy incisions.

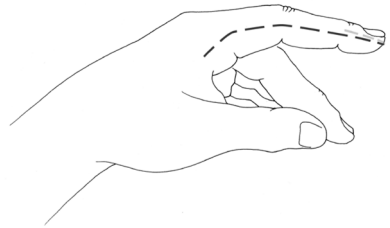


Fig. 24-3. Incision for finger fasciotomy.

Surgical Technique

Do not blindly clamp bleeding tissues because nearby nerves may be injured. If unable to control the bleeding with pressure, isolate the vessel under tourniquet control and tie off or clamp under direct vision.

- General or regional (block) anesthetic is required; local infiltration of anesthetic is inadequate. Epinephrine is never injected into the hands or fingers.
- Either the radial or ulnar artery may be ligated if necessary. Never ligate both.

- Debridement removes embedded foreign matter and dead tissue.
- Tissue, including skin, with marginal or questionable viability is left for subsequent evaluation to improve chances for optimal outcome.
- The fingers are not amputated unless irretrievably mangled.

Viable tissue, but potentially nonfunctional, is retained and stabilized for later reconstruction to include other locations.

Specific Tissue Management

- **Bone:** Provisional stabilization of fractures with Kirschner wires (K-wires), when skillfully done, may enhance patient comfort. Do not compromise future reconstructive efforts with overzealous initial management. A plaster splint may be the best option.
- **Tendon:** Minimal excision of tendons should be performed. No attempt at repair should be made in the field.
- **Nerve:** Do not excise nerve tissue. No attempt at repair should be made in the field.
- One may tag the cut ends of nerves and tendons if skillful to facilitate later repair. Monofilament nonabsorbable suture (6.0 or smaller) should be placed through the epineurium only of cut nerve ends.

Closure of wounds is delayed. However, exposed tendon, bone, and joint should be covered with viable skin, if possible, to prevent desiccation.

Dressing and Splinting

Splint the hand in the safe position (Fig. 24-4). The wrist is extended 20°, the metacarpophalangeal joints are flexed 70°–90°, and the fingers (proximal and distal interphalangeal joints) are in full extension.

- Fine-mesh gauze is first laid on the wounds and covered with a generous layer of fluffed gauze.

- The entire wound should be covered, but the fingertips left exposed, if possible, to monitor perfusion.
- A splint is applied, immobilizing all injured parts and extending one bone or joint beyond. A palmar plaster slab is routine, but a dorsal one may be added for additional stability.

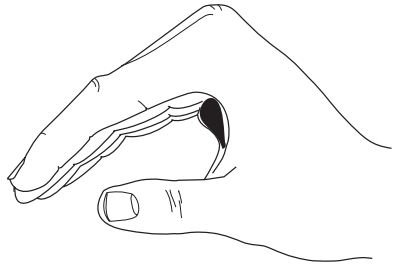


Fig. 24-4. Hand splint position.

The Foot

Penetrating injuries of the foot frequently result in prolonged morbidity and disability. Crush injuries and injuries from blast are more likely to result in an unsatisfactory result than are wounds made by low-velocity bullets or isolated fragments. This is especially true when there is loss of the heel pad, significant neurovascular injury, or when the deep plantar space has been contaminated. The ultimate goal of treatment of these injuries is a relatively pain-free, plantigrade foot with intact plantar sensation.

Evaluation and Initial Management

- The zone of injury, with both open and closed injuries of the foot, is often more extensive than is apparent with the initial inspection, and a low threshold for extensile debridement using longitudinal incisions should be observed.
- All clothing and boots should be removed and the entire foot exposed.
- The vascular status of the foot should be assessed by palpation of the dorsalis pedis and posterior tibial pulses or with use of a Doppler device if available. An assessment of capillary refill in the toes should also be made to assess peripheral perfusion.
- Transected major blood vessels to the foot should be double suture ligated to include plantar and dorsal pedal arteries and veins. Transected nerves may be tagged with suture for subsequent identification.

- At the time of debridement, small, contaminated, nonarticular bone fragments without soft-tissue attachment should be removed and discarded.
- High-volume, low-pressure irrigation for all open wounds is important as an adjunct to thorough surgical debridement. Vessel loop tissue tensioning technique may be used to prevent wound expansion during transport.

All wounds should be left open.

Sterile wet-to-dry dressings or negative pressure wound dressings should be placed for transport.

Injuries to the Hindfoot

- Severely comminuted, open fractures of the talus may require talectomy; but this decision should be left to higher levels of care.
- The talus is best debrided through an anterolateral approach to the ankle extended to the base of the fourth metatarsal.
- Penetrating wounds into the plantar aspect of the heel pad can be approached through a heel-splitting incision to avoid excessive undermining of this specialized skin.
- Transverse gunshot wounds of the hindfoot are best managed by medial and lateral incisions, with the majority of surgery performed laterally to avoid medial neurovascular structures.

Injuries to the Midfoot

- Tarsal and metatarsals are best approached through dorsal longitudinal incisions. Dorsal incision interosseous fasciotomies do not improve outcomes from potential compartment syndromes.
- Contamination of the deep plantar compartments of the foot is best managed through a plantar medial incision that begins 1 inch proximal and 1 inch posterior to the medial malleolus and extends across the medial arch ending on the plantar surface between the second and third metatarsal heads. The medial neurovascular structures must be identified during this approach. A full compartment release can also be performed through this incision.

Injuries to the Toes

- Every effort should be made to preserve the great toe.
- Amputation of the lateral toes is generally well-tolerated.

Foot Compartment Syndrome

- There are nine compartments in the foot.
 - The four interosseous compartments are bounded by the metatarsals medially and laterally by the dorsal interosseous fascia and the plantar interosseous fascia.
 - The lateral compartment is bounded by the fifth metatarsal shaft dorsally, the plantar aponeurosis laterally, and the intermuscular septum medially.
 - The central compartment is bounded by the intramuscular septum laterally and medially, the interosseous fascia dorsally, and the plantar aponeurosis plantarly.
 - The medial compartment is bounded by the inferior surface of the first metatarsal dorsally, the plantar aponeurosis extension medially, and the intramuscular septum laterally.
 - The calcaneal compartment contains the quadratus plantae muscle.
- There is no evidence that a double dorsal incision and interosseous compartment release alter outcomes, and, in fact, may increase infectious and painful complications.
- To spare the dorsal soft tissue and reduce subsequent risk for infection and complex regional pain syndrome, a single incision medial fasciotomy may be used.
- A medial approach to the foot is made through the medial compartment, reaching across the central compartment into the interosseous compartment dorsally and lateral compartment releasing all the way across the foot (see description in this chapter's section on Injuries to the Midfoot; also see Fig. 24-5).
 - As with all battle wounds, the fasciotomy is left open and is covered with a sterile dressing. Jacob's ladder vascular loops may be used to avoid wound expansion during transport.

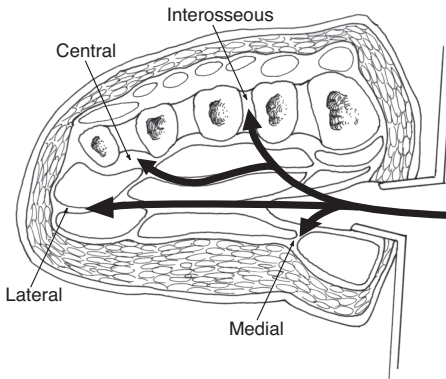


Fig. 24-5. Central compartment releases through medial approach.

Stabilization

- K-wires can be used for temporary stabilization following reduction. Alternatively, for larger segmental involvement, a spanning external fixator may be placed to regain overall anatomical length and alignment. Plate or screw fixation in the combat zone should usually be deferred to Role 4 facilities.
- A bivalved cast or splint is adequate for transport to a site of more definitive care.

Take care to avoid iatrogenic pressure sores by providing adequate padding to include bulky cotton padding. External fixation “kickstands” are useful, but only when external fixation is used for stabilization and not as a primary treatment.

Reference

Fuenfer MM, Creamer KM, eds. *Pediatric Surgery and Medicine for Hostile Environments*. Washington, DC: Department of the Army, Office of The Surgeon General, Borden Institute; 2010.

For Clinical Practice Guidelines, go to
http://usaisr.amedd.army.mil/clinical_practice_guidelines.html