

## Chapter 22

# Extremity Fractures

### Introduction

This chapter discusses two techniques for safe transportation of wounded service members with a long bone fracture: **transportation casts** and **temporary external fixation**. Both of these methods are acceptable for initial treatment of a casualty who will be evacuated out of theater. Precise indications for external fixator use versus casting have not been established.

Both transportation casts and external fixators are acceptable methods for the initial management of long bone fractures. In the end, the choice of initial fracture stabilization must be made on a case-by-case basis by the treating surgeon.

In general, indications for external fixator use include when the soft tissues need to be evaluated while en route, such as with a vascular injury; when other injuries make use of casting impractical, such as with a femur fracture and abdominal injury; or when the patients have extensive burns. The **advantages of external fixation** are that it allows for soft-tissue access, can be used for polytrauma patients, and has a minimal impact on the patient. A splint and bulky dressing may be added for better soft-tissue support.

**ADVANTAGES of transportation casts** are that they preserve the maximum number of surgical options, the soft tissues are well supported, and the casts are relatively low tech.

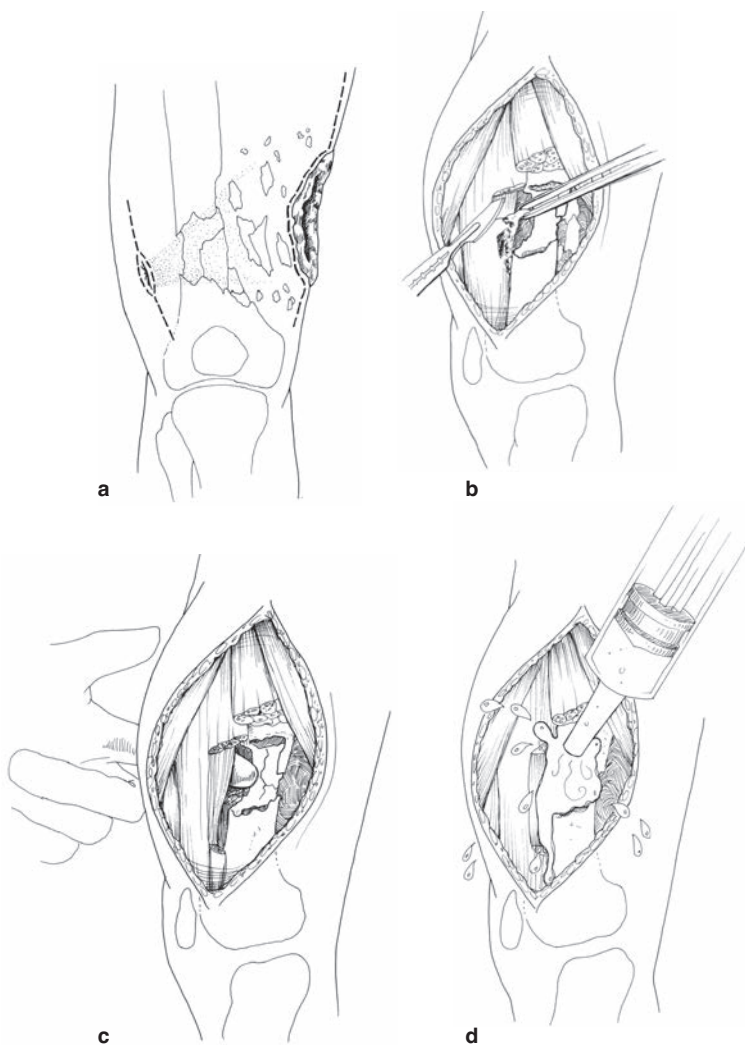
**DISADVANTAGES of transportation casts** are that they cover soft tissues, may not be suitable for polytrauma patients, and are more labor-intensive than external fixators.

Although standard in civilian trauma centers, intramedullary nailing of major long bone fractures is **contraindicated** in combat zone hospitals because of a variety of logistical and physiological constraints. This method may be used once a patient reaches Role 4 or other site where more definitive care can be provided. Intramedullary nailing has been performed successfully at Role 3 facilities on local nationals after appropriate initial damage control surgeries. However, this is an exception. Literature supporting this practice has very short follow-up with low patient follow-up. Local national surgeons must be able to care for patients with orthopaedic implants, particularly in the event they become infected. Historically, infected intramedullary devices have posed a significant management problem.

In this chapter, the term “**casting material**” is used to describe either plaster or fiberglass for constructing casts. Both are acceptable to use for transport casts.

### General Considerations of Wound Management

- Initial management.
  - Treat by debridement and irrigation as soon as feasible to prevent infection.
  - Tibia fractures are at high risk for infection following internal fixation (about 40%, historically).
  - Biplanar radiographs should be obtained when possible.
  - Neurovascular status of the extremity should be documented and checked repeatedly.
  - Internal fixation is contraindicated in the face of gross contamination.
  - Begin IV antibiotics as soon as possible and maintain throughout the evacuation chain. Use a broad-spectrum cephalosporin (Cefazolin 1 gram q8h).
- Wound incision/excision.
  - Guidelines as per Chapter 9, Soft-Tissue and Open Joint Injuries.
  - Use longitudinal incisions to obtain exposure.
  - Fascia is incised longitudinally to expose underlying structures and facilitate **compartment release**.



**Fig. 22-1.** Wound incision/excision.

- All foreign material in the operative field must be removed, along with dead bone and nonviable muscle (Fig. 22-1).
- Bone fragments should be retained only if they have a viable soft-tissue attachment or are part of a joint surface.
- Detached bone fragments are discarded.

- Irrigation is essential (Fig. 22-1d).
- Pulsatile lavage should be avoided.
- Closure of wounds.
  - Primary closure is **NOT** indicated in these contaminated wounds. Loose approximation of tissues with one or two retention sutures **MAY BE** appropriate to cover nerves, vessels, and tendons; but, there must be a provision for substantial free drainage.
  - Skin grafts, local flaps, and relaxing incisions are contraindicated in the initial management.
  - Delayed primary closure may be attempted, as described in Chapter 9, Soft-Tissue and Open Joint Injuries. This should be accomplished in a stable environment.
  - Negative pressure wound therapy is a useful adjunct in soft-tissue wound management.

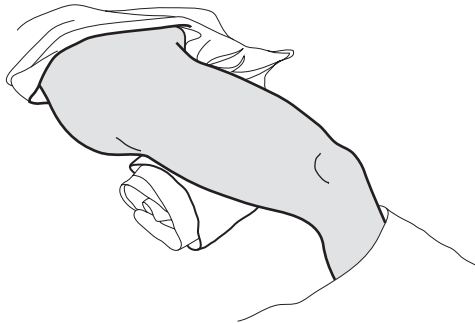
### **Bivalving Casts**

When bivalving a cast, splitting it into anterior and posterior halves is preferred. The purpose of bivalving is to accommodate soft-tissue swelling, thus lessening the chance of postcasting compartment syndrome. It is important that the underlying cast padding also be completely split underneath the cast cuts; otherwise, the cast padding can restrict swelling and a compartment syndrome could still develop. In an acute setting, **IF** a limb is casted, it is safest to bivalve the cast or simply immobilize with a splint.

### **External Fixation**

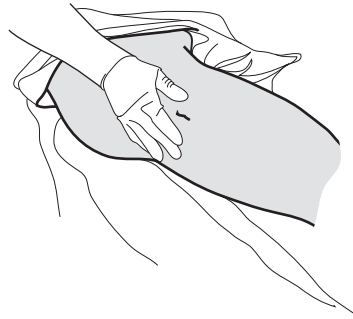
- General technique: the surgeon should be familiar with four standard constructs of external fixation for use in the initial care of bone and joint injuries: femur, tibia, knee, and ankle. External fixation can also be applied for humerus and ulna fractures, as needed.
  - A thorough understanding of the anatomy of the lower extremity is essential for safe insertion of fixator pins.
  - The external fixator for military purposes should be modular and allow for modification as healing progresses.
  - Application of the external fixator may be done without the use of plain films or fluoroscopy.
  - Pins can be inserted without power instruments.

- Enough pins should be placed to adequately stabilize the fracture for transport. This is usually two per clamp, but three may occasionally be required.
- The present external fixation system (Hoffmann frame) allows for the use of either single pin clamps or multipin clamps. Both clamps are acceptable to use in standard constructs.
- Multipin clamps provide greater stability and are the current fixators fielded. Dual pin placement (with multipin clamps) is described below. The technique for single pin placement is similar.
- **Femur diaphyseal fracture technique.**
  - The entire limb is prepared for surgery, from the anterior superior iliac spine to the toes.
  - A standard OR table or portable fracture table may be used.
  - An assistant should apply counterpressure while pins are inserted.
  - Precise reduction is not necessary. A padded “bump” under the thigh will help reduce the fracture (Fig. 22-2).
  - The position of the proximal femur should be identified by palpation. A 1-cm longitudinal stab incision is made over the midaxis, or midlateral axis, of the femur (Fig. 22-3). The pin closest to the fracture should be outside of the fracture hematoma and at least 3 fingerbreadths from the fracture (Fig. 22-4).



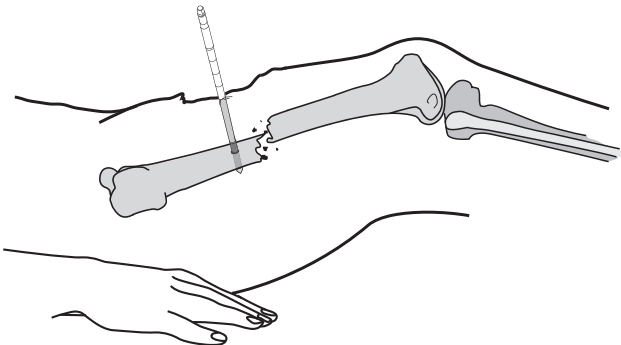
**Fig. 22-2.** Placing a towel underneath the thigh helps to reproduce the bow of the femur.

- Spread soft tissue bluntly down to the bone. Insert a pin through this opening and when reaching the bone, assess its midpoint by sweeping the pin anteriorly and posteriorly (Fig. 22-5). Your assistant should provide stability and counterpressure. Two taps on the end of the bit brace will indent the bone and stabilize the pin for insertion. Apex pins are placed by hand or power. Use 5-mm half-pins. Insert the pin in the midportion of the bone and advance through both the near and far cortices of the bone (Fig. 22-6). The pin will move easier as it enters the intermedullary canal and then becomes more difficult to drive as it enters the far cortex.



**Fig. 22-3.** Place a 1-cm longitudinal incision in line with the midlateral axis of the femur.

- Place a multipin clamp over the inserted pin. Ideally, the pin should occupy one of the end positions (eg, position 1 or 5; Fig. 22-7).
- Using the clamp as a guide, insert a second pin through the clamp. An assistant should hold the clamp. Ensure that the clamp is aligned with the bone and that bicortical pur-



**Fig. 22-4.** Pins should be placed outside of the fracture hematoma and at least 3 fingerbreadths from the fracture.

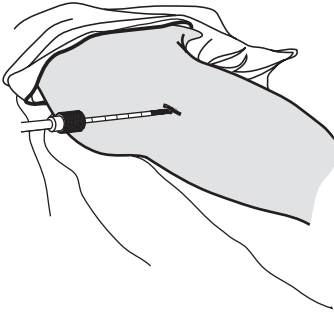


Fig. 22-5. Femoral pin placement.



Fig. 22-6. Bicortical placement of 5-mm half-pin.

chase is obtained. The second pin must be parallel to the first pin. To ensure they are parallel, it can be helpful to use the clamp as a guide for placing the second pin. Use the pin sites that are the farthest apart on the clamp as possible for biomechanical stability (clamp positions 1 and 5 are best; see Fig. 22-7). A third pin may be inserted if needed for additional clamp stability.

- Repeat this technique when inserting

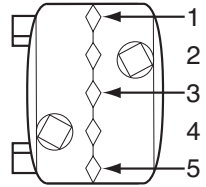


Fig. 22-7. Multipin clamp showing positions 1-5.

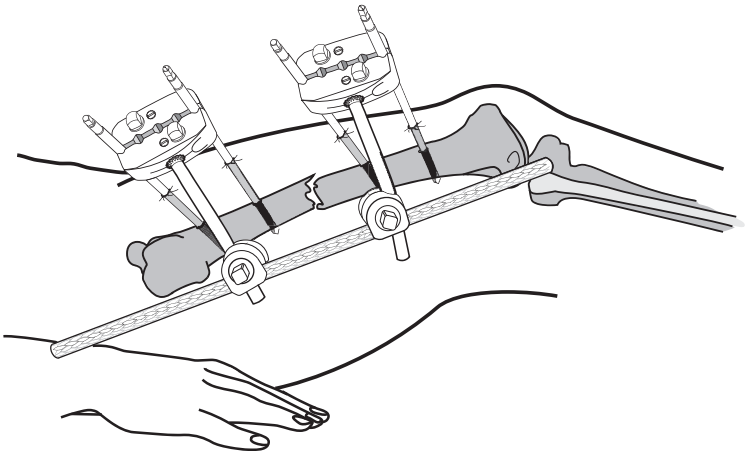


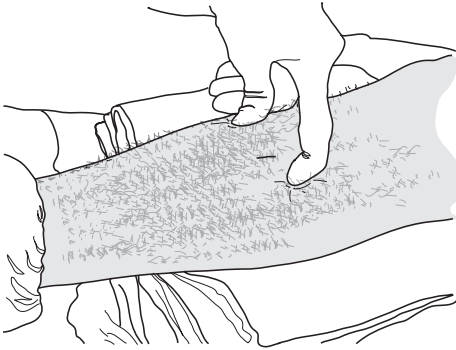
Fig. 22-8. Frame applied and fracture grossly reduced. Lateral placement of stabilizing rod is preferred. Consider use of multiple rods for increased stability.

pins and applying the multipin clamp to the distal femoral fracture fragment.

- Connect the two clamps with elbows, bar-to-bar clamps, and two longitudinal bars placed parallel to each other (Fig. 22-8).
- Reduce the fracture with longitudinal traction. Manipulating the fracture fragments using the clamps may be helpful. Once adequate reduction is achieved, tighten all of the connections. Precise reduction is not necessary.

● **Tibia shaft fracture technique.**

- Place a 1-cm longitudinal incision over the midportion of the anteromedial tibia (Fig. 22-9). The pin closest to the

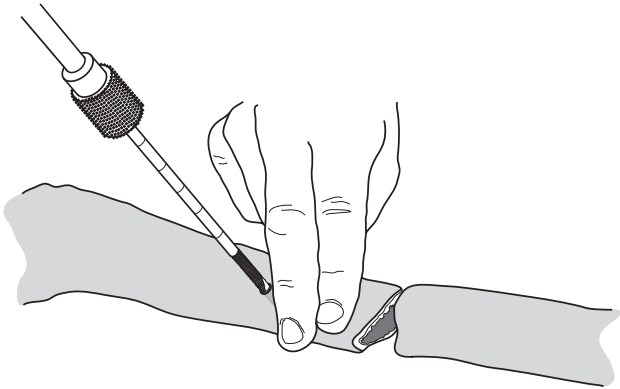


**Fig. 22-9.** Palpation of the anterior and posterior margins of the medial face of the tibia where a 1-cm incision has been made midway between these two points.

fracture site should be outside the hematoma and at least 2–3 fingerbreadths away from the fracture site (Fig. 22-10).

- Insert the first pin into either the proximal or distal fragment. Place the pin perpendicular to the subcutaneous border of the tibia and centered across the width of the tibia. Ensure that pins engage both cortices (Fig. 22-11).
- Using the clamp as a guide, insert a second pin through the clamp. An assistant should hold the clamp. Align the clamp with the bone and advance pin through both cortices. The second pin **must** be parallel to the first. Use the pin sites as far apart on the clamp as possible for biomechanical stability (positions 1 and 5 in Fig. 22-7). The second pin

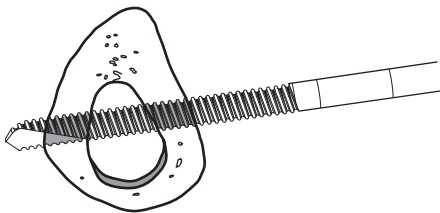




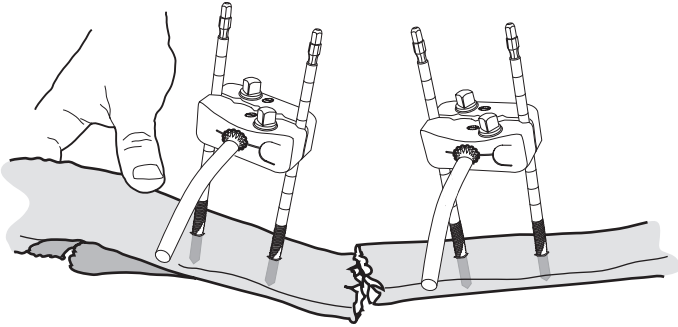
**Fig. 22-10.** The anteromedial surface is the safest location for tibial pins. Pins should be a minimum of 2 or 3 fingerbreadths from the fracture site.

should be through the opening farthest away from the fracture site.

- Apply a second multipin clamp and two pins in the same manner to the other main fracture fragment (Fig. 22-12). Connect the two clamps via two elbows, bar-to-bar clamps, and a single bar (Fig. 22-13).
- Most combat-related fractures are comminuted. Therefore, a second bar should be added for increased fracture stabilization (Fig. 22-14). Use a single bar for stable fractures only.
- Confirm reduction with available means.
- **Technique to span knee.**
  - Indications are proximal tibia fractures, distal femur



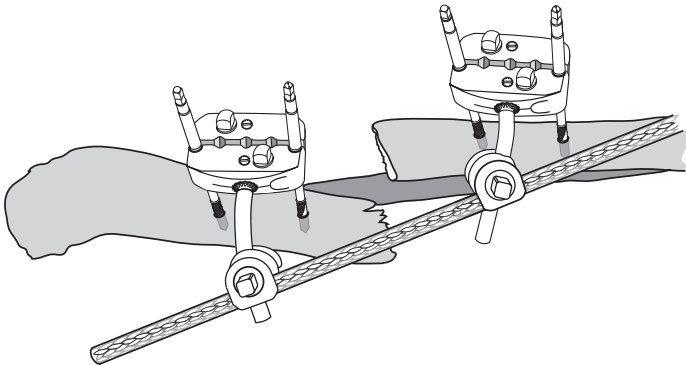
**Fig. 22-11.** Bicortical placement of tibial pins.



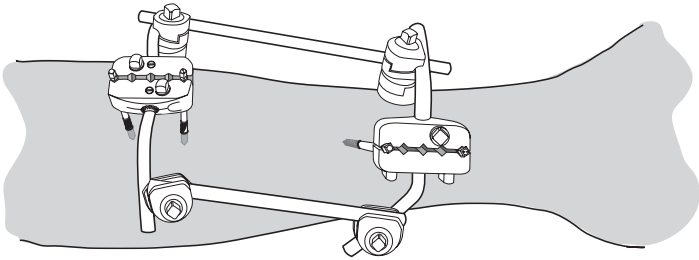
**Fig. 22-12.** Application of the second multipin clamp and two pins. Add 30-degree elbows to the two sets of multipin clamps. Point the elbows in a direction that will position the bar(s) away from open wounds and allow for the best access.

fractures or extensive knee injuries, or vascular repairs in the popliteal fossa.

- Check the distal vascular status of the limb prior to and after the procedure. If there is a vascular injury, refer to Chapter 25, Vascular Injuries.
- An assistant will be required to help apply the frame.



**Fig. 22-13.** Addition of the cross-bar and two bar-to-bar clamps. Apply longitudinal traction to reduce the fracture and then tighten the frame in alignment.

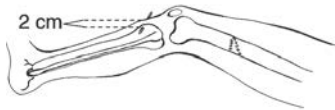

**Fig. 22-14.** The two-bar apparatus is a more stable construct for typical, unstable tibial fractures. This requires the use of two kits.

- General reduction maneuver should be longitudinal traction with slight ( $10^{\circ}$ – $15^{\circ}$ ) flexion at the knee.
- Pins are placed anteromedial on the proximal tibia and anterolateral on the distal femur. Pin placement should be outside the zone of injury, at least 3 fingerbreadths from a fracture site and outside the knee joint. A longitudinal stab incision is made over the mid-anterolateral aspect of the femur and the pin inserted at a 45-degree angle to the long axis of the bone. Depending on the fracture configuration, it may also be placed directly anteriorly, although it is generally better to avoid pin placement through the quadriceps tendon.
- Blunt dissection is used to create a corridor to the bone.
- A single pin is inserted by hand or power through both cortices of the bone.
- A multipin clamp is used as a guide for a second pin. The second pin **must** be parallel to the first pin and also be bicortical—care should be taken to maintain pin alignment. The proximal tibia should be palpated on the anteromedial surface, and the anterior-posterior border should be identified. Midway anterior-posterior, a 1-cm longitudinal stab incision should be made, followed by blunt, soft-tissue dissection to the bone.
- A multipin clamp should be used as a guide to insert a second pin in the proximal tibia.
- The two pin clusters (femur and tibia) should be connected via 2 elbows, 2 bar-to-bar clamps, and 1 bar. The knee should be aligned.

- A second bar should be added in the manner described previously.
- **Technique to span ankle.**
  - An assistant will be required to help apply the frame and reduce the ankle.
  - General indications are for open distal tibia fractures and open ankle wounds.
  - Pins should be inserted on the anteromedial surface of the tibia and on the medial aspect of the calcaneus.
  - Check the distal vascular status prior to and after the procedure. Mark where the posterior tibial and dorsalis pedis artery pulses can be felt.
  - Palpate the anteromedial border of the tibia. Make a 1-cm longitudinal incision midway between the anterior-posterior border of the tibia. Insert the most distal pin on the tibia outside the zone of injury, at least 3 fingerbreadths from the fracture site.
  - Using a multipin clamp as a guide, insert a second pin in the tibia proximal to the first pin. The pin **must** be parallel and aligned with the longitudinal axis of the first pin.
  - Palpate the medial border of the calcaneus. Make a longitudinal incision over the calcaneus **avoiding the posterior neurovascular structures**: dissect to the bone with a blunt instrument and insert the pin. When available, insert a centrally threaded pin from medial to lateral. The pin insertion point should be the junction of posterior and middle one-third distance between medial malleolus and posterior calcaneus tuberosity. If using two half pins, then apply in posterior half of this line.
  - Using a multipin clamp as a guide, insert a second pin in the calcaneus.
  - Connect the 2 clamps via 2 elbows, 2 bar-to-bar clamps, and 1 bar.
- **Skeletal traction.**
  - Skeletal traction provides a quick means to immobilize fractures with a minimum of technical support.
  - External fixation is preferred because it is more manageable in the transport environment.
  - Currently, traction equipment is hard to find at field

- hospitals.
- Indications.
    - ◆ Patients who are expected to have more than one procedure in the same forward hospital prior to evacuation.
    - ◆ Large casualty load.
  - Technique.
    - ◆ Large, threaded Steinmann pins are used to obtain skeletal traction of a femur or tibia.
    - ◆ Aseptic preparation of a pin site is necessary prior to placement.
    - ◆ Apply local anesthetic to planned pin site.
    - ◆ Incise skin and dissect to bone bluntly.
    - ◆ For femur fractures, incision is made 2 cm posterior and lateral to the tibial tuberosity (deep to the tibial tuberosity, as in Fig. 22-15). Place pin from lateral to medial completely through the proximal tibia. Place the



**Fig. 22-15.** Appropriate site for placement of proximal tibial traction pin.

- thigh and leg on the bed, and apply longitudinal traction of 20–40 lbs.
- ◆ Apply a Thomas splint with a Pierson device, with weight applied midthigh (10–20 lbs), to the leg (10–20 lbs), and to the traction pin (20–40 lbs) to obtain balanced skeletal traction.
  - ◆ For tibial fractures, incise medially 2 cm anterior and 2 cm cephalad from the posterior calcaneus. Place the pin from medial to lateral across the calcaneus. Place the leg on the bed balanced and apply traction to the calcaneal pin (10–20 lbs).
  - ◆ Wait at least 30 minutes after applying traction to obtain radiographs.
- **Care in the evacuation chain.**

- When planning procedures, consider the potential for complications during air evacuation.
- Consider medication supply for transport (see Chapter 4, Aeromedical Evacuation).
- Skeletal traction should **not** be used for transportation.
- Casts should be bivalved. Monitor extremity neurovascular status during transport because **casts may act as tourniquets due to tissue swelling**.
- All documentation, including radiographs, should accompany the patient.
- Well-padded splints can be used with and without external fixation with large open wounds, such as blast injuries. Circumferential dressings should be avoided because they can be constricting.

For Clinical Practice Guidelines, go to  
[http://usaisr.amedd.army.mil/clinical\\_practice\\_  
guidelines.html](http://usaisr.amedd.army.mil/clinical_practice_guidelines.html)