

Face and Neck Injuries

Introduction

Immediate recognition and appropriate management of airway compromise is critical to survival. The best method to quickly evaluate airway compromise is to ask the patient to speak. If the patients can speak intelligibly, then the airway is intact, they have enough pulmonary reserve to generate sound, and their Glasgow Coma Scale score is most likely >8. If the patient cannot speak, the airway needs to be emergently secured.

- Face and neck injuries can be immediately life-threatening and difficult to manage. **Focus on ABC priorities.**
- During **airway control**, maintain **cervical spine immobilization** in patients with head and neck injuries.
- **Control of bleeding** begins with direct pressure. If bleeding cannot be controlled with direct pressure, immediate operative intervention is necessary. **DO NOT** blindly clamp vessels in the neck.
- **Complete assessment** of remaining injuries (fractures, lacerations, esophageal injury, ocular injuries, etc) occurs only after the ABCs have been addressed.

Immediate Management of Facial Injuries

- Airway.
 - The most common site of airway obstruction in the trauma patient with head and/or neck injuries is at the base of tongue and upper pharynx. These patients typically present with obstructed breathing marked by **stertor**, a coarse snoring noise most pronounced on inspiration. Blunt or penetrating neck injuries may also result in laryngeal trauma that can present with inspiratory **stridor**, a harsh,

high-pitched sound. In either case, a noisy airway is a compromised airway, and steps must be taken immediately to relieve the obstruction. Common causes of traumatic airway obstruction include:

- ◆ Blood or secretions.
- ◆ Soft-tissue edema.
- ◆ Collapse of the tongue base against the posterior pharynx.
- ◆ A fractured, free-floating mandible may obstruct the airway due to tongue base retrodisplacement.
- ◆ Displaced tooth fragments may become foreign bodies.
- Maneuvers to relieve upper airway obstruction:
 - ◆ Chin lift or jaw-thrust maneuver.
 - ◆ Remove foreign bodies (strong suction, Magill forceps).
 - ◆ Place adjunctive airway device (nasal trumpet or oropharyngeal airway). DO NOT use nasal tubes in patients with suspected skull base fractures.
 - ◆ Endotracheal intubation.
 - ◆ Cricothyroidotomy (preferred emergent surgical airway technique) or urgent tracheotomy may become necessary.
- Cervical spine.
 - Up to 10% of patients with significant blunt facial injuries will also have a cervical spine injury.
 - ◆ **The neck should never be hyperextended.**
 - ◆ Intubation should only be performed with in-line neck stabilization.
- Vascular injury.
 - Injuries to the face are often accompanied by **significant bleeding**.
 - Control of facial vascular injuries should progress from simple wound compression for minor bleeding to possible vessel ligation for more significant bleeding.

Vessel ligation should only be performed under direct visualization and after careful identification of the bleeding vessel. Blind clamping of bleeding areas should be avoided because critical structures, such as the facial nerve or parotid duct, are susceptible to injury.

- ◆ Wound packing with a pressure dressing may control active craniofacial bleeding. Hemostatic gauze may also be used.
- Intraoral bleeding must be controlled to ensure a safe airway.
 - ◆ Do not pack the oropharynx in an awake patient due to the risk of airway compromise. First secure the airway with an endotracheal tube or surgical airway, if necessary. Moistened, rolled gauze is excellent material for packing the oropharynx.
 - ◆ Irrigation and gram-positive antibiotic coverage (eg, clindamycin) should be used liberally for penetrating injuries of the face.
- Evaluation.
 - Once the casualty is stabilized, gently cleanse dried blood and foreign bodies from wound sites to evaluate the depth and extent of injury.
 - The bony orbits, maxilla, forehead, and mandible should be palpated for stepoffs or mobile segments suggestive of a fracture.
 - A complete intraoral examination includes inspection and palpation of all mucosal surfaces for lacerations, avulsions, ecchymosis, bony stepoffs, malocclusion, and dental integrity.
 - **In the awake patient, malocclusion indicates a probable fracture.**
 - Perform a cranial nerve examination to assess vision, gross hearing, facial sensation, facial muscle movement, tongue mobility, **and** extraocular movements.
 - Consult an ophthalmologist for decreased vision on gross visual field testing, diplopia, or decreased ocular mobility.
 - If the intercanthal distance measures >40 mm (approximately the width of the patient's eye), the patient should be evaluated with a CT scan and treated for a possible naso-orbital-ethmoid (NOE) fracture.
- If an NOE fracture is suspected, do not instrument the nose. There may be a tear in the dura, and instrumentation may contaminate the cerebrospinal fluid (CSF) via the skull base defect.

Facial Bone Fractures

Facial bone fractures should be realigned and fixed in correct anatomical position with dental wires or titanium plates and screws to restore normal appearance and function of the face and surrounding structures.

With the exception of fractures that significantly alter normal dental occlusion or compromise the airway, repair of facial fractures may be delayed for up to 10 days after injury. Open fractures may be debrided, irrigated, and closed temporarily should time not permit immediate repair.

● **Mandible fractures.**

- Second most commonly fractured bone of the face (after the nose).
- Subcondylar fractures are most common.
- Multiple mandible fractures are present in 50% of cases.
- Patients typically present with limited jaw mobility or malocclusion.
- A Panorex is the single best plain film (but is usually unavailable in the field environment); a plain film mandible series serves as a less reliable, but satisfactory, study (might overlook subcondylar fractures).
- Fine cut (1–3 mm) CT scan will delineate nearly all mandible fractures.
- Treatment is determined by the location and severity of the fracture and the condition of existing dentition.
 - ◆ Remove only teeth that are severely loose or fractured with exposed pulp.
 - ◆ Teeth in the line of a fracture, if stable and not impeding the occlusion, should be maintained.
- Nondisplaced subcondylar fractures in patients with normal occlusion may be treated simply with a soft diet and limited wear of a Kevlar helmet and protective mask.
- Immediate reduction of the mandible fracture and improvement of occlusion (and patient comfort) can be accomplished with a bridle wire (24 or 25 gauge) placed around at least two teeth on either side of the fracture.
- More severe fractures may require immobilization with maxillary-mandibular fixation (MMF) for 6 weeks.

- Place commercially made arch bars onto the facial aspect of the maxillary and mandibular teeth.
 - ◆ Arch bars are fixed to the teeth with simple circumferential (24 or 25 gauge) wires (Fig. 13-1).
 - ◆ After proper occlusion is established, the maxillary arch bar is fixed to the mandibular arch bar with wires or elastic bands.
 - ◆ If portions of the mandible have been avulsed or the fragments are extremely contaminated, an external, biphasic splint should be placed to maintain alignment.
 - ◆ **Wire cutters must always be with the patient who is in MMF.**

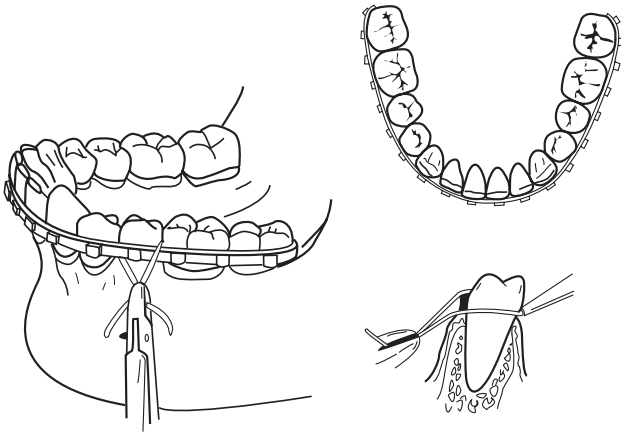


Fig. 13-1. Arch bar applications.

- The airway must be closely monitored in the patient with maxillofacial trauma who is placed into MMF. **Consider the ability to monitor patients with MMF during aeromedical evacuation before placing a patient in MMF.**
 - Open reduction and internal fixation with a mandible plate across fracture sites may obviate the need for MMF.
- **Nasal fractures.**
 - Most common fracture.
 - ◆ Control of epistaxis: Gauze or sponge packing or balloon. Hemostatic gauze may also be helpful for brisk epistaxis (Fig. 13-2).

- Diagnosed clinically by the appearance and mobility of the nasal bones.

The patient's septum should be evaluated for the presence of a septal hematoma that, if present, must be immediately drained by incision, followed by packing to prevent delayed complications.

- Treat by closed reduction of the fractured bones and/or septum into their correct anatomical positions up to 7 days after fracture.
 - ◆ Place a blunt elevator (Sayre) into the nasal cavity to elevate the depressed bony segment while simultaneously repositioning the bone with the surgeon's thumb placed externally.
- The nose may then be fixed with tape or a splint to maintain the reduction.
- **Maxillofacial fractures.**
 - Includes orbital, zygomaticomaxillary complex, frontal bone, and Le Fort fractures.
 - Potentially life-threatening due to loss of airway, hemorrhage, or spinal injury.
 - Fragment wounds of the maxillary sinus are commonly seen and may require surgical removal of retained fragments (can delay until specialist available).

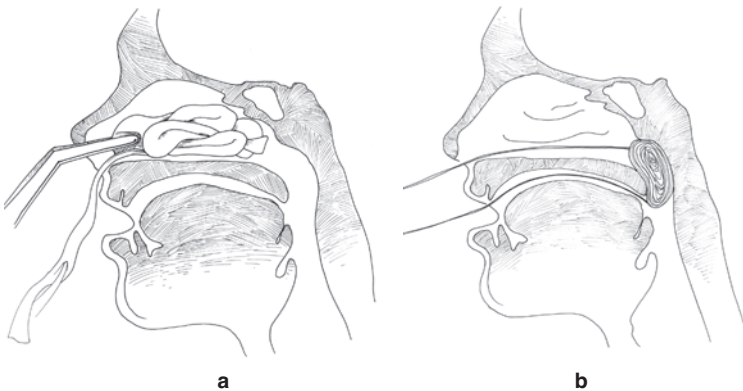


Fig. 13-2. (a) Anterior and (b) posterior packing of the nose.

- Midface fractures (Le Fort).
 - ◆ Requires “significant” trauma.
 - ◆ High incidence of associated spine, brain, and orbital injuries.
 - ◆ Significant hemorrhage from lacerations of the internal maxillary artery and its branches.
 - ◇ Can be difficult to control.
 - ◇ May be life-threatening.
 - ◇ Treat by protecting the airway, controlling hemorrhage with pressure dressings or packing, and reducing fractures.
 - ◆ A surgical airway is sometimes necessary. Edema may cause immediate or delayed airway compromise.
 - ◆ Can be difficult to diagnose.
 - ◇ Manipulate the hard palate and midface while stabilizing the skull. Place the thumb and forefinger of one hand on the nasal bridge to stabilize and, with the other hand, determine mobility of the maxilla by placing the thumb on the alveolus and forefinger on the palate and attempt gentle distraction in an anterior-posterior direction.
 - ◇ Penetrating facial injury fractures may not follow classic Le Fort patterns and often have significant associated external and internal soft-tissue injuries.
 - ◇ Systematically palpate the head and face looking for deformities, crepitus, tenderness, ecchymosis, or subconjunctival hemorrhages that might suggest fractures.
- Classification of facial fractures by Le Fort (Fig. 13-3).
 - ◆ **I**—Fracture separates the entire alveolar process from maxilla.
 - ◆ **II**—Separation of midface, including the nasal bone, from the orbit (pyramidal).
 - ◆ **III**—Detachment of the face from the skull (craniofacial disarticulation).
- Treatment.
 - ◆ ABCs.
 - ◆ If nasal intubation is necessary, **extremely careful placement** is mandatory to avoid cribriform plate or anterior cranial fossa penetration.

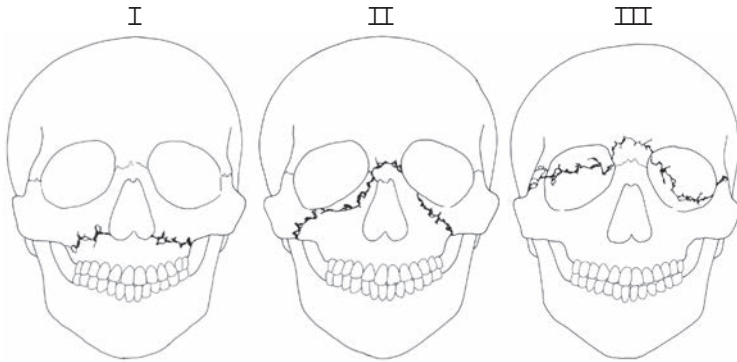


Fig. 13-3. Le Fort facial fracture classifications.

- ◆ Check CNS and vision.
- ◆ Can immobilize the maxilla by using the mandible as a splint (wires/arch bars, **with wire cutters at bedside**). It is much easier to place patient into MMF if either a nasal airway or tracheostomy is used.
- ◆ Control nasopharyngeal and/or oropharyngeal hemorrhage by tamponade as previously described.
- Definitive surgical repair.
 - ◆ **Not an emergency** once the airway and hemorrhage are controlled.
 - ◆ Requires expertise in ENT, oral and maxillofacial surgery, plastic surgery, and/or ophthalmology.
 - ◆ Repair is often time-consuming.
 - ◆ Open fracture reductions require titanium plating systems and equipment that are usually unavailable in the field.

Soft-Tissue Injuries

● General principles.

- Avoid injury to surrounding structures, such as the facial nerve or parotid duct.
- Wounds should be gently cleansed with saline and light scrub solutions; foreign bodies should be meticulously cleaned from wounds prior to closure. Profuse irrigation is indicated.
- Sharply debride devascularized wound edges **minimally**.

- **Facial lacerations should be closed in layers within 24 hours of injury unless severely contaminated.** Heavily contaminated wounds and large avulsion injuries may be treated with packing, regular debridement, local wound care, and closed in a delayed fashion. The use of local flaps, skin grafts, or free vascularized tissue transfers may be necessary to cover large, soft-tissue defects of the face and neck.
 - ◆ Use 4-0 or 5-0 absorbable suture for subcutaneous/dermal layers.
 - ◆ Use 5-0 or 6-0 nonabsorbable sutures on facial skin.
 - ◆ Remove sutures in 5–7 days.
- **Facial nerve injuries.**

Facial nerve branches that are lacerated at a site anterior to a vertical line drawn down from the lateral canthus of the eye do not need to be surgically reapproximated because these branches are very small and will spontaneously regenerate with good return of facial function.

- Carefully examine for facial nerve function in all **five** branches as soon as possible after injury (Fig. 13-4).

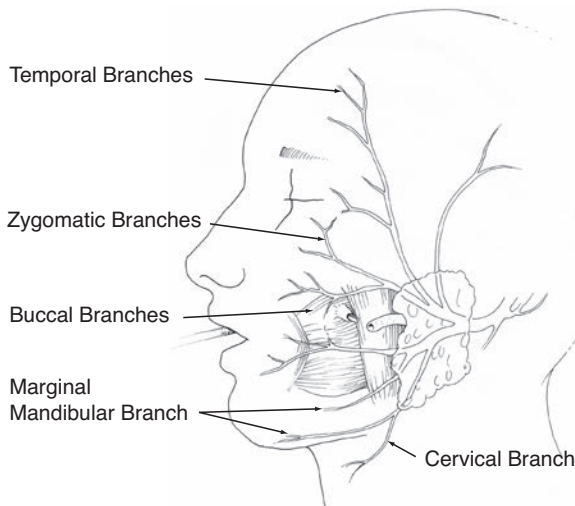


Fig. 13-4. Branches of the facial nerve parotid duct injury.

- The severed ends of the nerve may be located in the wound with a nerve stimulator for up to 3 days after injury.
- Cut nerve ends should be primarily reapproximated with three or four fine (9-0) nylon sutures placed through the epineurium.
- If a gap exists between the severed ends of the facial nerve due to tissue loss, an interposition graft may be placed using a section of the great auricular nerve to bridge the gap.
- In heavily contaminated wounds that cannot be closed primarily, the severed ends of the nerve should be located and tagged for identification and repair at a later time.
- Parotid duct injuries.
 - Evaluate penetrating wounds of the parotid/buccal regions of the face for salivary leakage due to a lacerated parotid duct (Fig. 13-5).
 - ◆ The wound may be manually compressed and inspected for salivary leakage.
 - ◆ If the parotid duct is injured by a facial laceration, the distal end of the duct may be identified by placing a lacrimal probe through the intraoral opening of the duct located near the maxillary second molar (see Fig. 13-4).
 - ◆ The proximal end may be identified by compressing the wound and looking for saliva.
 - Repair with absorbable (6-0) sutures (see Fig. 13-5).
 - A stent may be placed into the duct to facilitate closure and prevent stenosis.

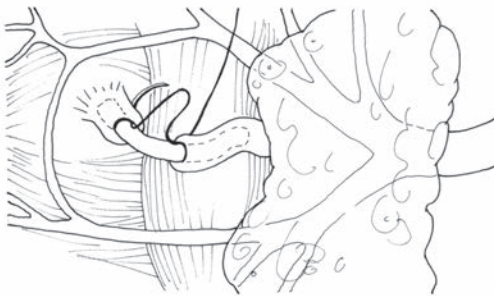

Fig. 13-5. Repair of the parotid duct.

- ◆ Possible stents include lacrimal stents, large (size 0) polypropylene sutures, or long angiocaths.
- ◆ Stents may be sutured to the buccal mucosa and removed after 7 days.
- Auricular injuries.
 - Strongly consider antibiotic coverage for *Pseudomonas* and *Staphylococcus* infections with exposed cartilage (especially in burns of the auricle).
 - Preserve skin and soft tissue for maximal coverage of exposed cartilage.
 - Cartilage should be preserved unless severely damaged. **Minimize use of suture in cartilage or perichondrium.**
 - Auricular hematomas should be incised and drained to prevent cartilage destruction. A drain or bolster should be placed for 48 hours after incision and drainage.

Penetrating Neck Trauma

- Introduction.
 - Vascular injuries occur in 20% and aerodigestive tract injuries in 10% of cases.
 - Immediate mortality is primarily due to exsanguination or airway compromise.
 - Esophageal injury, which may result in mediastinitis and intractable sepsis, is a significant cause of delayed morbidity and mortality.
- **Anatomy.**

The neck is divided into three zones to aid decision-making for diagnostic tests and surgical strategy. In each zone, the primary structures at risk of injury are different (Fig. 13-6).

- **Zone I (clavicle to cricoid):** The structures of concern include large vessels of the thoracic outlet (subclavian artery and vein, common carotid artery), the lung, and the brachial plexus.
- **Zone II (cricoid to angle of mandible):** Structures of concern include the common carotid artery, internal jugular vein, esophagus, and trachea.
- **Zone III (angle of mandible to base of skull):** The structure of primary concern is the internal carotid artery.

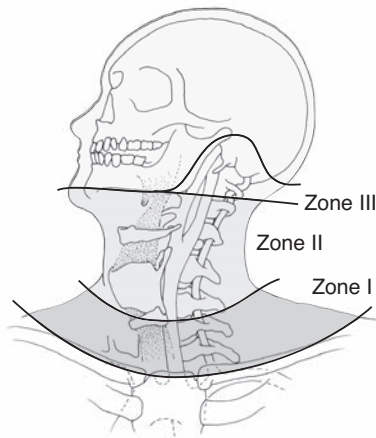


Fig. 13-6. Zones of the neck.

- Immediate management.
 - ABCs.
 - Obtain chest, soft-tissue neck radiographs, and CT angiography if patient is stable.
 - Address tetanus status and antibiotic prophylaxis.
- Operative strategy.
 - Neck wounds with suspected platysma violation should only be probed or explored in the operating room. An approach via an incision along the anterior border of the sternocleidomastoid muscle is preferred (Fig. 13-7).
 - If the platysma is not violated, surgical intervention is not indicated.
 - If the patient with penetrating neck trauma (PNT) is symptomatic, neck exploration is indicated. If the patient is asymptomatic, workup to include CT angiography, panendoscopy (direct laryngoscopy, bronchoscopy, and esophagoscopy), and a water-soluble contrast swallow study should be considered. Neck exploration is indicated if the workup reveals pathology.
 - Selective management based on clinical signs and symptoms should be considered for all patients with PNT, regardless of the zones involved. Nonoperative management of zone II injuries with platysma violation is acceptable in the stable

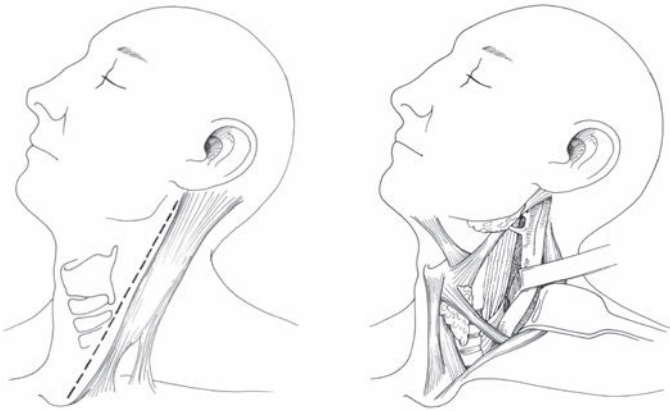


Fig. 13-7. Neck exposure of zone II.

patient with a negative workup as described previously. Selective management of PNT can only be performed at facilities with the resources to complete the workup and observe the patient. Surgical exposure of zones I and III is difficult and requires a high degree of surgical expertise. Nonoperative management of PNT in stable patients with zone I or zone III injuries is preferred.

- ◆ PNT patients without clinical signs of injury (see below) may be evacuated without operative intervention if the appropriate workup (CTA, panendoscopy, or swallow study) is negative.
- Important clinical signs indicating probable injuries (pertinent to all three zones).
 - ◆ Signs of vascular injury:
 - ◇ Current or history of significant bleeding.
 - ◇ Expanding hematoma.
 - ◇ Bruit or thrill in the neck.
 - ◇ Hypotension.
 - ◇ Dyspnea, hoarseness, or stridor.
 - ◇ Absent or decreased pulses in neck or arm.
 - ◇ Focal neurological deficit or mental status change.
 - ◇ Chest radiograph findings of hemothorax or mediastinal widening.

- ◆ Signs of aerodigestive injury (esophagus, trachea, larynx):
 - ◇ Crepitus or subcutaneous emphysema.
 - ◇ Dyspnea or stridor.
 - ◇ Air bubbling from wound.
 - ◇ Tenderness or pain over trachea; odynophagia.
 - ◇ Hoarse or abnormal voice.
 - ◇ Hematemesis or hemoptysis.

Surgical Principles

- The groin and upper thigh should be surgically prepped for possible greater saphenous vein interposition graft or patch angioplasty.
- Exsanguinating hemorrhage from injured vessels at the base of the skull (zone III) may be controlled with inflation of a directed catheter (Fogarty or Foley).
- Repair esophageal injuries in two layers and place passive Penrose drains. A muscle flap should be interposed between repaired esophageal and tracheal injuries to prevent a fistula. Obtain a contrast swallow study 7 days after repair and before feeding.
- Repair laryngotracheal injuries with either absorbable or non-absorbable suture, stainless steel wires, or microplates. It is important to search for concomitant esophageal injuries as well.
- Major (significant segmental loss or >50% diameter loss) tracheal injuries should be managed with an endotracheal tube placed through the distal tracheal opening and placement of passive drains.
- **Vertebral artery injury.**
 - Suspect if bleeding continues from a posterolateral neck wound despite pressure on the carotid artery.
 - Preoperative angiography localizes the site of injury and establishes the existence of a patent contralateral vertebral artery.
 - Exposure of the vertebral artery may be difficult. When the contralateral vertebral artery is intact, ligation proximal and distal to the injury will likely be necessary.
 - Bone wax or surgical clips may be useful for controlling vertebral artery bleeding. May require removing the lateral aspect of the transverse process for access.

- **Intraoral injuries.**
 - Occult internal carotid artery injury should be suspected in patients with penetrating intraoral injuries LATERAL to the tonsillar fossa. Neurological testing and monitoring are critical, and a CT scan and/or angiography should be considered. A “sentinel” bleed should be considered if, after a penetrating lateral oral injury, the patient bleeds a small amount only to stop. A carotid artery blowout or occlusion may follow. Carotid artery intimal dissection may occur in patients with blunt lateral oropharyngeal trauma or in patients with high-velocity penetrating injury near the skull base that does not directly violate the carotid artery.
- **Internal carotid artery injury.**
 - Should be surgically repaired unless there is profound hemiplegia with coma (Glasgow Coma Scale score <8), in which case the common or internal carotid arteries may be ligated. The external carotid artery and its branches may always be ligated.
 - Mortality is high in patients with severe neurological deficits; carotid ligation is justifiable in complete occlusion of the entire carotid system and depending on the triage situation.
 - Small carotid perforations should be minimally debrided and closed with 6-0 polypropylene.
 - Vein angioplasty is required with loss of vascular tissue.
 - If there is extensive destruction, segmental resection and restitution of flow are established by:
 - ◆ End-to-end anastomosis (if the vessel is sufficiently elastic to permit).
 - ◆ Interposition vein graft.
 - ◆ External carotid swing-over and interposition.
 - ◆ Temporary (24–48 hours) shunt as part of a damage control maneuver.
 - A distal clot may be removed by gentle use of a balloon catheter prior to shunt insertion or repair.
- **Internal jugular vein injury.**
 - Preferably repaired with suture.
 - Ligation is acceptable if the contralateral internal jugular is patent.

● **Larynx.**

- After immediate control of the airway has been achieved by intubation or tracheotomy (**not through the wound in the larynx!**), a complete airway evaluation by direct laryngoscopy and bronchoscopy must be performed.
- Debridement of laryngotracheal injuries must be careful and conservative. A fragmented larynx or trachea should be reapproximated and sutured with extraluminal sutures for tracheal injuries and nonabsorbable sutures or microplates used for laryngeal fractures. All exposed laryngeal cartilage should be covered with mucosa. A buccal mucosa graft may be used when large intraluminal mucosal defects are present.
- Management of laryngeal trauma includes accurate reduction and stabilization of fractures; mucosa-to-mucosa closure of lacerations; and use of a soft stent if there is extensive cartilaginous damage, structural support is decreased, or the anterior commissure is involved. The stent may need to be temporarily placed for 4–6 weeks to maintain correct anatomical architecture and requires a complementary tracheotomy.
- Excessive removal of cartilage and mucosa must be avoided to prevent tracheal or laryngeal stenosis.

● **Laryngotracheal injuries.**

- If laryngotracheal separation is suspected (massive crepitus over the larynx/trachea) in an otherwise “stable” airway, endotracheal intubation should not be undertaken because this may cause a partial separation to become a complete separation, and/or the endotracheal tube may enter the mediastinum and occlude the distal airway.
- Awake tracheotomy/cricothyroidotomy under local anesthesia without paralysis is preferable in patients with laryngeal trauma. Adequate local anesthesia can be achieved with a 4% (40 mg/cc) lidocaine nebulizer, 2 cc in 3 cc of saline, and direct administration of 4% lidocaine into the trachea for an awake tracheotomy (in addition to local anesthetic infiltration into the skin and subcutaneous tissues). When instilling anesthesia into the airway, aspirate and ensure that air enters the syringe before injecting.

- **Tracheal injury and reconstruction.**
 - A tracheostomy tube may be placed through small anterior wounds of the cervical trachea.
 - Repair simple lacerations with absorbable suture. Care should be taken to avoid constricting the airway when closing defects. Pedicled muscle may be used to cover small tracheal defects.
 - End-to-end tracheal anastomosis should be performed with interrupted, extraluminal 4-0 nylon or polypropylene suture.
 - The anterior cricoid ring does not need to be closed, and careless reapproximation of a fractured cricoid may result in subglottic stenosis.
 - Up to 5 cm of trachea can be resected with proximal and distal mobilization.
 - Mobilize anteriorly and posteriorly to preserve lateral blood supply. A suprahyoid release may be helpful.
 - Remove an oral endotracheal tube as soon as possible post-op.
 - Consider chin-to-chest sutures (2-0 nylon sutures through mandibular periosteum and clavicular periosteum) for 10 days postoperatively to avoid accidental wound separation with head extension in patients with tracheal separation repairs.
- **Esophageal and hypopharyngeal injury and repair.**
 - Commonly associated with injuries to the airway and great vessels.
 - Subcutaneous emphysema, pneumomediastinum, saliva in the neck, hemoptysis or blood-tinged saliva, odynophagia, and dysphagia are possible signs and symptoms of hypopharyngeal and esophageal injury. However, 25% of these injuries may be asymptomatic.
 - Missed injury is a major source of late morbidity / mortality.
 - Chest radiograph and esophagogram with water-soluble contrast are indicated in patients with suspected hypopharyngeal or esophageal injuries, but without a definitive indication for exploration. Esophagograms may have a false-negative rate as high as 20%. A negative water-soluble contrast study may be followed by a barium study to increase the test sensitivity.

- Insufflation with air in an open neck flooded with saline may aid in identification during exploration.
- Rigid and flexible esophagoscopy are complementary in the identification of hypopharyngeal and esophageal injuries.
- Debride devitalized tissue.
- Close esophageal wounds in two layers with absorbable sutures.
- Pedicled muscle flaps help to bolster repairs.
- Drain wounds with Penrose drains.
- Contrast swallow study at 7 days post-op and prior to oral intake.
- Leave drains in place until swallow study performed and oral diet resumed.
- Extensive injuries may require lateral cervical esophagostomy and is preferred to closure under tension.
- **Combined injuries.**
 - Esophageal injuries combined with airway or vascular injury require separation with healthy tissue. Strap muscles are ideal, but the use of a pedicled sternocleidomastoid muscle is an alternative if the strap muscles are devitalized.
- **Esophageal fistula.**
 - 10%–30% incidence.
 - Due to inadequate debridement, devascularization of remaining esophageal wall, closure under tension, or infection.
 - Treatment.
 - ◆ NPO.
 - ◆ Maintain nutrition with tube feeds.
 - ◆ Ensure fistula control with drains.
 - ◆ Weekly water-soluble contrast study to assess closure.
 - ◆ Resume oral intake prior to removing drains.

Skull Base, Temporal Bone, and Otological Injury

- All patients with suspected temporal bone fractures or acoustic barotrauma, with or without tympanic membrane perforation, should undergo audiometric testing (with an audiometer) as soon as feasible. In addition, these patients deserve special consideration because of the high incidence of other neurological and cognitive problems that may occur with these injuries.

- Documentation of facial nerve function is performed on all awake patients and as early as possible in a patient who has regained consciousness. Delineation between delayed versus sudden onset facial paralysis is critical for determining the prognosis and management of facial nerve injuries. Also critical is the delineation between a distal and proximal nerve injury. If a proximal injury is present, one or more facial nerve branches may be affected.
 - Be as complete as possible in describing facial motion, even if not technically accurate. Accurate documentation may spare the patient from unwarranted surgical intervention to explore the entire length of the facial nerve. It is desirable to accurately describe the motion of EACH branch of the facial nerve. An injury of the main trunk will most likely result in all branches being equally affected. Eyelid movement does not ensure that the facial nerve is intact, since the levator palpebrae muscle is innervated by the oculomotor nerve and will remain intact despite facial nerve injury.
 - In the absence of medical contraindications, systemic steroids should be administered for suspected facial nerve paralysis. Crush injuries to the facial nerve may present with delayed-onset paralysis, and the severity and course of the paresis may be improved with systemic administration of steroids.
- Skull base fractures are often occult. Assess the patient for evidence of basilar skull fractures (Battle's sign, raccoon eyes, CSF rhinorrhea or otorrhea). Any patient with blood or CSF in the ear canal should be presumed to have a temporal bone fracture.
- **Carefully examine the external auditory canal, but do not instrument the canal if there is CSF or blood in the canal. If a temporal bone fracture is present and the dura is not intact, instrumentation may introduce bacteria into the CSF with resulting meningitis. Sterile instruments may be used to suction and debride the ear canal with microscopic visualization.**
- A tear in the lining of the external auditory canal suggests a temporal bone fracture.
 - When a temporal bone fracture is suspected, facial nerve function and hearing must be assessed.

- Dry tympanic membrane perforations can be observed. The vast majority of them will heal spontaneously, but the patient should be followed for potential complications or failure to heal. Wet or contaminated tympanic membrane perforations should be treated with ototopical antibiotics for at least 10 days (4 drops twice daily of ofloxacin are adequate). The patient should be instructed to keep the ears dry (avoid water contamination).
- Hemotympanum may be seen with acoustic and temporal bone trauma. These patients will have hearing loss. If available, perform a gross audiological evaluation with tuning forks. Hemotympanum-associated hearing loss should resolve itself in about 6–8 weeks.
 - Examination of hearing can be accomplished with a single 512-Hz tuning fork.
 - ◆ The handle of a vibrating tuning fork is placed on the mastoid tip and then alternately the tuning fork is held in the air outside the external canal while asking the patient which is heard louder (Rinne test). Documentation as $A > B$ (air $>$ bone) or $B > A$ is sufficient (do not report as “positive” or “negative”):
 - ◇ Air conduction greater than bone conduction with a 512-Hz tuning fork is normal.
 - ◇ Bone conduction greater than air is suggestive of a conductive hearing loss in the affected ear.
 - ◆ Place the 512-Hz tuning fork on the frontal bone/nasal dorsum or central incisors (Weber test).
 - ◇ The sound will be heard loudest in the ear with a conductive hearing loss or in the ear contralateral to an ear with sensorineural hearing loss.
 - ◇ If the Rinne test suggests a conductive hearing loss (ie, bone conduction $>$ air conduction), the tuning fork should be heard louder on the side with the conductive loss.
- Any otological blast injury or injury to the temporal bone may result in tinnitus. Management is expectant because tinnitus following acoustic trauma usually resolves spontaneously. Hearing should be evaluated and documented.

- Any patient with acoustic trauma should be removed from noisy environments and have serial audiograms performed over 14–21 days to assess recovery. Recovery of most traumatic hearing loss is expected, except in cases of temporal bone fractures, very large tympanic membrane perforations, or penetrating temporal bone injuries.
- Steroids should be considered if sensorineural hearing loss is suspected and documented after a blast injury or acoustic trauma. A dose of 1 mg/kg of prednisone is appropriate. If there is no improvement after 5 days of therapy, steroids may be discontinued. If improvement is noted, a taper over 3–4 weeks is indicated. Be mindful that steroids may alter a patient's affect, impair judgment, or impair wound healing.
- Dizziness and vertigo may result from acoustic trauma. If true vertigo (observed nystagmus) exists after an otological injury, the patient may have a perilymphatic fistula from depression of the stapes into the oval window or rupture of the round window. These patients may also have tinnitus and hearing loss. If a perilymphatic fistula is suspected, the patient should be seen by an otolaryngologist as soon as possible to prevent further damage to the inner ear.

For Clinical Practice Guidelines, go to
http://usaisr.amedd.army.mil/clinical_practice_guidelines.html

