

Wounds and Injuries of the Spinal Column and Cord

Introduction

Combat injuries of the spinal column, with or without associated spinal cord injury, differ from those encountered in civilian practice. These injuries are often open, contaminated, and usually associated with other organ injuries.

Following the ABCs (airway, breathing, circulation) of Advanced Trauma Life Support, management principles include:

- Initial spine stabilization to prevent neurological deterioration.
- Diagnosis.
- Definitive spinal stabilization.
- Functional recovery.

In complete injuries, the likelihood of neurological recovery is minimal and is not influenced by emergent surgical intervention. Incomplete injuries with neurological deterioration, however, may benefit from emergent surgical decompression. One must assume, until spinal shock has abated, that patients with a significant spinal column injury have the potential for a concomitant neurological deficit, and should be treated and transported accordingly.

Classification

Four discriminators must be considered in the classification and treatment of spinal injuries.

- Is the injury open or closed?
- Neurological status: complete vs incomplete vs intact.

- Complete injury demonstrates no neurological function **below the level of injury** after the period of spinal shock (usually 48–72 hours, evidenced by the return of the bulbocavernosus reflex).
- Location of the injury: cervical, thoracic, lumbar, or sacral.
- Degree of bony and ligamentous disruption: stable vs unstable.

Pathophysiology of Injury to the Spinal Cord

- Injury to the spinal cord is the result of both primary and secondary mechanisms.
 - **PRIMARY:** The initial mechanical injury due to local deformation and energy transmission (primary injury cascade). This phase of the injury is most often unpreventable.
 - ◆ High-velocity missile wounds in the paravertebral area can cause injuries even without direct trauma. Stretching of the tissue around the missile's path during formation of the temporary cavity, or fragmentation of the projectile and bone resulting in secondary missiles, causes injury without any direct destruction of the spinal column.

The destructive nature of high-velocity wounds explains the futility of decompressive laminectomy in the management of these wounds.

- **SECONDARY:** The cascade of biochemical and cellular processes initiated by the primary process that causes cellular damage and even cell death (secondary injury cascade).

Critical care of spinal cord injury patients includes attempts to minimize secondary injury from hypoxia, hypotension, hyperthermia, and edema.

Mechanical Integrity of the Vertebral Column

The vertebral column is composed of three structural columns (Table 20-1):

- Anterior.
- Middle.
- Posterior.

Table 20-1. Support of the Spinal Column

Column	Bony Elements	Soft-Tissue Elements
Anterior	Anterior two-thirds of vertebral body	Anterior longitudinal ligament Anterior annulus fibrosus
Middle	Posterior one-third of vertebral body Pedicles	Posterior longitudinal ligament Posterior annulus fibrosus
Posterior	Lamina Spinous processes Facet joints	Ligamentum flavum Interspinous ligaments

- Injuries occur by either direct penetrating forces or a combination of flexion, axial loading, rotation, and distraction forces.
- **Instability may occur from either blunt injury of the vertebral column or gunshot/ fragmentation wounds. The incidence of instability is significantly higher in explosion-related injuries.**
- Cervical instability by lateral radiograph (must include the C7/T1 junction) is suggested by:
 - 3.5 mm or greater sagittal displacement or translation.
 - Angulation of 11° or more on the lateral view.
 - The accuracy and, therefore, the role of flexion and extension lateral radiographs to assess for cervical stability are limited in the acute injury setting. If cervical stability remains in question following initial assessment, the safest course of action is to provide external cervical immobilization until stability can be definitively established.

CT is very effective in demonstrating spinal morphology and has become available in some field environments.

Instability must be presumed (and the spine stabilized) in any patient with:

- **Complaints of a sense of instability (holds head in hands).**
- **Vertebral column pain.**
- **Tenderness in the midline over the spinous processes.**
- **Neurological deficit.**
- **Altered mental status.**
- **SUSPECTED, but NOT PROVEN, injury.**

Patient Transport

On the battlefield, preservation of the life of the casualty and medic is of paramount importance. In these circumstances, EVACUATION TO A MORE SECURE AREA TAKES PRECEDENCE OVER SPINE IMMOBILIZATION. Data do not support the use of cervical collars and spine boards for PENETRATING spine injuries on the battlefield.

Extrication

- **Cervical spine.**
 - **The neck should never be hyperextended.**
 - If an airway is needed.
 - ◆ If appropriate, attempt endotracheal intubation with in-line neck stabilization.
 - ◆ Cricothyroidotomy may be necessary if intubation fails.
 - The head should be maintained in alignment with the body.
 - ◆ Requires several people, including one designated to stabilize the neck.
 - ◆ Log roll, with the most experienced person stabilizing the neck.
 - A stiff cervical collar and sandbags provide stabilization of the neck during transport. The head and body should be secured to the extrication device.
- **Thoracic and lumbar spine.**
 - Use the log roll or two-man carry.
 - ◆ The two-man carry alone does not protect the cervical spine. Ensure C-spine protection.

- In the absence of a spine board, makeshift litters can be fashioned from local materials.

Anatomical Considerations

Cervical Spine

All potentially unstable cervical spine injuries should be immobilized in a cervical collar, unless halo immobilization is required. However, halo devices should not be placed until the patient is evacuated to a theater asset where a neurosurgeon or orthopaedic spine surgeon is available for halo placement and reduction of these injuries.

● **Indications for halo use:**

- The role of halo immobilization in the acute combat setting is quite limited. In nonpenetrating trauma to the cervical spine, immobilization with a cervical collar or sandbags is preferable until arrival at a definitive treatment site.
- Should traction be indicated for cervical spine injuries (eg, facet joint dislocations or burst fractures with a tenuous neurological status), the Gardner-Wells tongs should be applied and sufficient weight (generally 10–20 lbs) placed **in line** with the spine (Fig. 20-1; Table 20-2). If traction is applied, radiographs must be obtained to be certain that no undiagnosed ligamentous injury has been exacerbated by the weight. **Do not treat injuries to the occipitocervical articulation with traction because this could result in disarticulation of the head from the cervical spine.**
- The role of collar immobilization in penetrating injuries to the cervical spine is less well established. Soft-tissue care is compromised by the collar's position and, in general, penetrating injuries coupled with osseous instability should be managed in Gardner-Wells traction.

Thoracic and Lumbar Spine

- Although the thoracic rib cage contributes considerable rotatory stability, it does not protect completely against injuries.
- The vascular supply of the spinal cord is most vulnerable between T4 and T6, where the canal is most narrow. Even a minor deformity may result in cord injury.

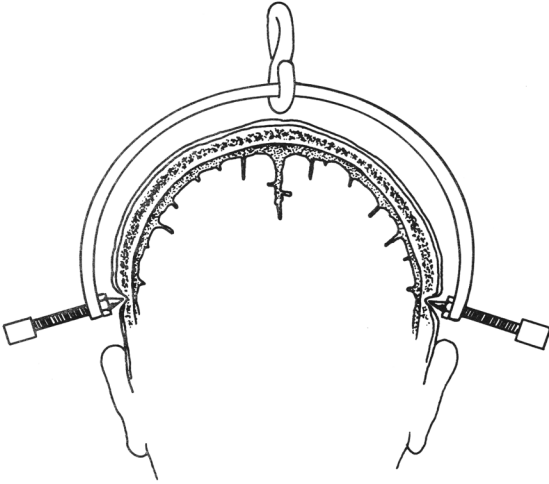


Fig. 20-1. Gardner-Wells tongs.

- The most common place for compression injuries is at the thoracolumbar junction between T10 and L2 in the civilian population. However, a very high preponderance of low lumbar burst fractures (L3 and below) occurs in the military population. These injuries are quite distinct in that the pelvic brim connotes “inherent” stability for these fractures.
- Most burst fractures result from an axial load and occur at the thoracolumbar junction. These fractures are associated with compromise of the spinal canal and progressive angular deformity. They are often associated with significant neurological injury.
- Evaluation for surgical stabilization and spinal cord decompression should be done with advanced imaging, such as CT and/or MRI.

When complex wounds involving the head, thorax, abdomen, or extremities coexist with vertebral column injuries, lifesaving measures take precedence over the definitive diagnosis and management of spinal column and cord problems. During these interventions, further injury to the unstable spine must be prevented by appropriate protective measures.

Table 20-2. Application of Gardner-Wells Tongs

Steps	Procedure	Comment
1	Inspect Insertion Site: 1 cm superior to pin in line with the external auditory meatus.	Rule out depressed skull fracture in this area.
2	Shave and Prep Pin Insertion Site	
3	Inject Local Anesthetic: Inject 2–3 cc of 1% Xylocaine or equivalent agent 1 cm above each ear in line with the external auditory meatus.	May omit if patient is unconscious.
4	Advance Gardner-Wells Tong Pins: Insert pins into skull by symmetrically tightening the knobs.	A spring-loaded device in one of the two pins will protrude when the pins are appropriately seated. (A data plate on the tongs provides additional information.)
5	Apply Skeletal Traction: Use a pulley fixed to the head of the litter or frame to direct horizontal traction to the tongs.	Use the 5-lb rule (ie, 5 lbs of weight for each level of injury). High cervical fractures usually require minimal traction to reduce. Monitor with series radiographs. The tong-pin site requires anterior or posterior positioning to adjust for cervical spine flexing or extension as indicated.
6	Elevate Head of Litter: Use blocks to provide body weight counter traction.	The knot in the cord should not be permitted to drift up against the pulley. Should this occur, traction is no longer being applied.
7	Decrease Traction Weight: When radiographs confirm that reduction is adequate, decrease traction to 5–15 lbs.	Unreducible or unstable fractures should be maintained in moderate traction until surgical intervention. If neurological deterioration occurs, immediate surgical intervention must be considered.
8	Daily Pin Care	Cleanse tracts with saline and apply antibiotic ointment to the pin sites. Maintain pin force (see step 4) by tightening as necessary to keep spring-loaded device in the protruded position.

(Table 20-2 continues)

Table 20-2 *continued*

9	Turn Patient Appropriately: Use Stryker, Foster, or similar frame and turn patient every 4 hours.	When initially prone, obtain radiographs to ensure that the reduction is maintained. If reduction is not maintained when the patient is prone, rotate the patient only between the 30° right and left quarter positions. Use of a circle electric bed is contraindicated with injuries of the spinal cord or column.
10	If Satisfactory Alignment Cannot Be Obtained, Further Workup Is Necessary	Consider myelogram, CT scan, tomograms, and neurosurgical/orthopaedic consultations.

Emergent Surgery

Emergent spine surgery for penetrating or closed injuries of the spinal cord is indicated only in the presence of neurological deterioration.

- **Penetrating spine injuries.**
 - Injuries associated with a hollow viscus should undergo appropriate treatment of the viscus injury without **extensive** debridement of the spinal injury, followed by appropriate broad-spectrum antibiotics for 1–2 weeks. Inadequate debridement and irrigation may lead to meningitis.
 - Removal of a fragment from the spinal canal is indicated for patients with neurological deterioration.
 - In neurologically stable patients with fragments in the cervical canal, delaying surgery for 7–10 days reduces problems with dural leak and makes dural repair more straightforward.
 - Casualties not requiring immediate surgery may be observed with spine immobilization and treated with 3 days of IV antibiotics. Surgical stabilization can be performed following evacuation.

General Management Considerations

Neurogenic Shock

- Traumatically induced sympathectomy with spinal cord injury.
- Symptoms include bradycardia and hypotension.
- Treatment:
 - Volume resuscitation to maintain systolic blood pressure >90 mm Hg.
 - May use phenylephrine (50–300 µg/min) or dopamine (2–10 µg/kg/min) to maintain blood pressure. (First treat with fluid resuscitation and oxygen before starting pressor support.)

Gastrointestinal Tract

- Ileus is common and requires use of a nasogastric tube.
- Stress ulcer prevention using medical prophylaxis.
- Bowel training includes a schedule of suppositories and may be initiated within 1 week of injury.

Deep Vein Thrombosis

- Start mechanical prophylaxis immediately.
- Initiate chemical prophylaxis after acute bleeding has stopped (see Chapter 11, Critical Care).

Bladder Dysfunction

- Failure to decompress the bladder may lead to autonomic dysreflexia and a hypertensive crisis.
- The bladder is emptied by intermittent or indwelling catheterization.
- Antibiotic prophylaxis for the urinary tract is not advised.

Decubitus Ulcers

- Skin breakdown begins within 30 minutes in the immobilized hypotensive patient.
- **For prolonged transport, the casualty should be removed from the hard spine board and placed on a litter.**
- Frequent turning and padding of prominences and diligence on the part of caretakers are essential to protect the insensate limbs.

- All bony prominences are inspected daily.
- Physical therapy is started early to maintain range of motion in all joints to make seating and perineal care easier.

For Clinical Practice Guidelines, go to
[http://usaisr.amedd.army.mil/clinical_practice_
guidelines.html](http://usaisr.amedd.army.mil/clinical_practice_guidelines.html)