Chapter 18

CRANIAL NERVE INJURIES

SCOTT B. ROOFE, MD, FACS*; CAROLINE M. KOLB, MD†; AND JARED SEIBERT, MD‡

INTRODUCTION

CRANIAL NERVE V

CRANIAL NERVE VII
- **Evaluation**
- **Imaging**
- **Electrodiagnostic Testing**
- **Eye Care**
- **Nerve Exploration**
- **Nerve Repair**
- **Interposition Grafting**
- **Intratemporal Injuries**
- **Facial Nerve Decompression**

LOWER CRANIAL NERVES, IX THROUGH XII

CRANIAL NERVE IX

CRANIAL NERVE X

CRANIAL NERVE XI

CRANIAL NERVE XII

SUMMARY

CASE PRESENTATIONS
- **Case Study 18-1**
- **Case Study 18-2**

*Colonel, Medical Corps, US Army; Program Director, Otolaryngology Residency, Tripler Army Medical Center, 1 Jarrett White Road, Honolulu, Hawaii 96859-5000; Assistant Professor of Surgery, Uniformed Services University of the Health Sciences
†Major, Medical Corps, US Army; Staff Otolaryngologist, Fort Belvoir Community Hospital, 9300 Dewitt Loop, Fort Belvoir, Virginia 20112
‡Captain, Medical Corps, US Army; Otolaryngology Resident, Tripler Army Medical Center, 1 Jarrett White Road, Honolulu, Hawaii 96859-5000

INTRODUCTION

Injuries to the head and neck rank as some of the most common injuries suffered in the current combat environment. These injuries often lead to extensive bony and soft tissue disruption, which places the cranial nerves at increased risk for damage. Functional deficits of any of these nerves can be devastating to both appearance and function. Due to the complex nature of combat-related wounds, it is not uncommon to have patients with multiple cranial nerve injuries. Therefore, early identification, careful assessment, and timely management in the acute setting are critical to maximizing the outcomes for these patients. The otolaryngologist clearly has a vital role in the management of nearly all cranial nerve injuries. However, in the combat environment, this specialty generally focuses on deficits arising from cranial nerves VII and VIII as well as the lower cranial nerves, IX through XII. A detailed discussion of auditory and vestibular injuries involving the eighth nerve is provided in Chapter 35, Cranial Nerve Injuries. This chapter will focus primarily on cranial nerves V, VII, and IX through XII.

CRANIAL NERVE V

Patients with extensive lacerations, combat wounds, and skull base injuries are at high risk for damage to any of the branches of the trigeminal nerve. For example, the infraorbital nerve is frequently damaged in any maxillary or orbital injury, with a risk of temporary or permanent hypesthesia. Hypesthesia in this region may be regarded as an annoyance only, but extensive hypesthesia from other branches of the fifth cranial nerve may interfere with a wide variety of functional activities related to eating and communication, particularly periorally. Numbness in the ophthalmic distribution of cranial nerve V may place the eye at risk due to decreased sensation of the cornea. In addition to loss of sensation, injury to these branches may also result in prolonged neuralgias with chronic pain or hypersensitivity in these areas. It is important to be aware of the distribution of the nerve branches and their relationship to the area of injury. Some practitioners advocate primary repair under binocular microscopy in these settings, particularly for readily identifiable peripheral terminal branches, most often at the time of repair of other injuries.[1] However, fifth nerve repair in the acute setting should not delay evacuation or treatment of other, more pressing injuries. This repair may be more appropriate in the setting of delayed microvascular reconstruction of extensive traumatic defects.

CRANIAL NERVE VII

According to the Joint Theater Trauma Registry, cranial nerve VII was the most commonly injured cranial nerve associated with craniomaxillofacial injuries suffered during operations in Afghanistan and Iraq.[2] Damage to the facial nerve may be the most devastating of the cranial nerve injuries due its central role in facial appearance, eye protection, eating, and communication, including speech and displays of emotion. A variety of mechanisms in combat can result in facial nerve paresis or paralysis, including blunt trauma from vehicle accidents, falls, and assaults, as well as penetrating injuries from gunshot wounds and blast injuries. Both blunt and penetrating trauma can result in massive soft tissue and bony injury that may compromise the facial nerve.

Evaluation

Evaluation of patients with known or suspected facial nerve injury should begin with the ABCs (airway, breathing, circulation) to identify life-threatening injuries. Once any of these injuries have been addressed, a thorough history and physical examination should be performed, with particular focus on the onset and degree of facial nerve injury. In many patients, the ability to obtain a history or complete a physical examination is severely limited by associated life-threatening injuries or a reduced level of consciousness. The appropriate measures necessary to manage traumatic injuries and control the airway may limit evaluation. In these instances, there are several methods by which facial nerve function may still be assessed in the acute setting. For example, the first responders may be able to report the degree of facial motion upon presentation, but this assessment may be unreliable if the patient was unconscious or the team focused on other injuries or airway concerns. Any residual facial motion, such as a grimace to painful stimuli if the patient is not completely sedated or obtunded, may be useful. The surgeon may also consider lightening the patient's sedation if possible in order to facilitate assessment of facial motion. At times, the acute assessment of the facial nerve is not possible. Because of these factors and overshadowing injuries, facial paralysis may not

be noted until after a few days. These cases should be categorized as "unestablished in onset" and treated similarly to the immediate-onset cases.[3]

Once an accurate assessment can be performed, facial function is frequently recorded using the House-Brackmann scale.[4] This method is designed to grade injuries within or proximal to the intratemporal facial nerve. This scale is not designed for cases where the injury is distal to the pes anserinus and involves only certain branches. In these cases clinical evaluation should determine whether there is paresis or paralysis for each affected distal nerve branch.

The timing and severity of facial nerve dysfunction dictates the management, so it is critical to get an accurate assessment of facial function as soon after the injury as possible. The vast majority of patients with any residual motion at presentation are likely to recover good facial nerve function in the affected distribution without any intervention. However, patients with complete paralysis of immediate onset have a uniformly poor prognosis and should be considered for surgical exploration and management.

Imaging

Patients with traumatic facial nerve injuries should also be evaluated with computed tomography (CT) of the temporal and facial bones, which was available at most Role 3 facilities in theater. Imaging will likely help to determine the location and extent of injury as well as the best approach to repair and exploration. The location of shrapnel and bullet fragments can be widely divergent from the entry wound and can direct the surgeon to the site of injury. In some cases, obvious transection of the nerve may be identified.[5] CT angiography is also a valuable imaging tool in the presence of intratemporal injury to rule out any associated major vascular injury at the skull base.

Electrodiagnostic Testing

Electrophysiologic testing is unnecessary for patients with immediate onset of facial paralysis when imaging studies demonstrate clear evidence of facial nerve transection, because these patients typically should be explored.[5] Patients with immediate onset of paralysis, for whom imaging does not demonstrate a clear disruption, can be further evaluated with electrophysiologic testing. Some patients with paresis develop deterioration of facial function and progress to paralysis. Although most of these patients will have a good outcome, formal testing can help identify the small subset of patients who may benefit from facial nerve surgery.

The primary tests include electroneurography (ENoG) and electromyography (EMG), but these techniques are rarely available in a field environment. However, if patients are rapidly transferred to a referral facility with the capability, electrodiagnostic testing is recommended. ENoG showing greater than 95% degeneration when compared to the opposite side within 6 days has been shown to result in a uniformly poor prognosis, so facial nerve exploration is recommended in this situation. Patients with 95% degeneration between days 6 and 15 tend to have less severe nerve trauma but still have a poor prognosis. Therefore, these patients are also recommended for surgical intervention.[6] Intraoperative nerve stimulators are often readily available at Role 3 facilities in theater and can be utilized for stimulation of terminal nerve branches of a transected facial nerve up to 72 hours following injury.

Unlike ENoG, EMG can provide prognostic information after loss of nerve excitability and may be considered in the subacute period after transport to a higher role of care. After 10 to 14 days, if fibrillation potentials are detected confirming the presence of degenerating motor units, the vast majority of patients will have incomplete recovery. In contrast, if polyphasic reinnervation potentials are identified within 4 to 6 weeks after injury, a good recovery can be expected.[7]

Eye Care

Eye care is of the utmost importance with facial nerve dysfunction when incomplete eye closure is present. Ocular lubricants, including artificial tears and ophthalmic ointment, are implemented at a minimum. Taping, especially before bedtime, is recommended to keep the eye closed and the cornea protected. Temporary tarsorrhaphy may also be considered for eye closure, particularly if the patient is planned for transport. In addition, an ophthalmologist should be consulted for evaluation. Other more definitive protective eyelid procedures such as gold weight placement, permanent tarsorrhaphy, and lid shortening procedures are not recommended in the acute deployed setting but are appropriate for delayed management in patients with prolonged paralysis.

Nerve Exploration

The surgeon must have a high index of suspicion for distal facial nerve injury in any facial trauma, particularly when soft tissue lacerations are present. The approach to nerve exploration should be tailored to the individual patient and dictated by the location and nature of the wound and mechanism of injury.

The nerve should be thoroughly explored for nearly every case of paralysis. An exception exists, however, when the injury is medial to the lateral canthus and individual branches are involved. Further exploration and primary repair is not recommended in this instance because the patient usually recovers at least some function as axonal regeneration occurs.[8] Some associated synkinesis may occur after recovery, but it is generally of limited morbidity and can be addressed many months later with a variety of methods, including selective injection of botulinum toxin.[9]

Nerve exploration should be performed within 72 hours, if possible. After this time, due to Wallerian degeneration, there is no residual excitability of the nerve and peripheral stimulation cannot be used to assist in identifying the nerve. However, the ability to perform distal nerve stimulation may disappear before the 72-hour timeframe. Consequently, it is best to perform the exploration expeditiously. Disposable nerve stimulators are often available in theater and can be ordered from most facilities. The nerve stimulator is set at 0.5 to 1.0 mA, and each distal branch is stimulated as it is identified. Each terminal end should be prepared for immediate grafting or, if this is not feasible, they should be marked using dyed permanent 6-0 or 7-0 nylon or polypropylene suture or, alternatively, metallic clips.

A variety of well-known landmarks can be used to assist in nerve identification during exploration, including the tragal pointer and tympanomastoid suture line for the facial nerve trunk, the buccal branch coursing near the Stensen duct, and the marginal mandibular branch in the submandibular gland fascia. Cervical branch injury is of very limited morbidity and exploration and repair is not recommended. Further exploration may involve identification of the nerve as it exits the stylomastoid foramen through a parotidectomy approach, following its peripheral branches. The nerve should also be observed as it exits the stylomastoid foramen for any evidence of hematoma or edema, which may indicate the need for decompression in this region. With extratemporal blast injuries, however, despite the presence of edema and contusion of the nerve trunk, there is evidence that when the nerve is otherwise intact, conservative management without further surgery may be the best option.[10] These cases must be considered for management on an individual basis.

Nerve Repair

The facial nerve should be repaired in the acute setting if there is evidence of transection. However, delays may be needed in cases such as wound contamination, severe injuries requiring extensive reconstruction, requirement for immediate transfer, or inability to tolerate surgery. If any concerns exist about performing immediate repair, the transected facial nerve branches, both proximally and distally, should be tagged during wound exploration at their terminal ends as previously mentioned to facilitate identification at the time of definitive repair. As discussed below, some patients will need interposition grafting, but if no donor site is readily available, there may also be a need for delay. When possible, however, primary anastomosis should be performed using 8-0 or 9-0 permanent monofilament suture under magnified vision with surgical loupes or low power binocular microscopic vision. Multiple, evenly-spaced epineural sutures are adequate for coaptation.

If the proximal site of nerve transection is found at the main trunk near the pes anserinus, the short length of the proximal stump may make suturing for primary anastomosis very difficult. In other instances, the nerve may be transected at the stylomastoid foramen. In addition, fusion of the nerve sheath in the region just distal to the mastoid portion with the periosteum of the stylomastoid foramen and temporal bone makes this portion difficult to suture. In these cases, a mastoidectomy should be performed and consideration given to the use of an interposition graft due to the relative difficulty of mobilizing the intratemporal facial nerve.[3] Although the surgeon initially treating the patient in the acute phase should identify and mark the distal ends of the branches for later identification and grafting, it is recommended that the patient be transferred to a surgeon with expertise in dissection and repair of intratemporal facial nerve injuries due to the technically demanding nature of neurorrhaphy in this location.

Interposition Grafting

Tension-free repair is a critical element of successful nerve anastomosis. When this cannot be achieved using primary anastomosis, interposition cable grafts should be used.[11] There are several candidates for donor grafts, with the best choice based on individual circumstances. The great auricular nerve is an excellent option for defects of less than 10 cm and is readily identified in the operative field. Its size and fascicular pattern are similar to the facial nerve, and it has a distal branching pattern favorable for facial nerve grafting. Both sides of the neck should be prepared in the operative field in case the contralateral nerve is also needed. Alternatively, the cervical plexus, located deep to the sternocleidomastoid muscle, may be harvested with minimal morbidity when the great auricular nerve is unavailable. If a longer section is needed, particularly for reconstruction of multiple branches, the sural nerve should be utilized. The sural nerve provides up to

70 cm of length when all branches are dissected. The medial antebrachial cutaneous nerve may be used as an alternative.[11] When several branches are injured and require anastomosis, priority is given to the zygomatic and buccal branches due to their role in eye protection and facial expression, respectively.

Intratemporal Injuries

Intratemporal injuries may be categorized as penetrating or nonpenetrating injuries. Nonpenetrating injuries are related most often to blunt trauma and commonly result from assaults or motor vehicle accidents. Penetrating injuries in the combat environment are most often due to gunshot wounds or shrapnel and are more disruptive to the integrity of the nerve than blunt trauma. These injuries are also more often accompanied by other severe injuries, such as dural tears with cerebrospinal fluid leak, labyrinthine damage, and major vascular injury. Neurosurgical consultation is important for management of these patients. Evaluation includes high-resolution CT, carotid arteriography, and facial nerve electrical testing if available, as previously noted.

The mastoid segment of the facial nerve is the most commonly involved segment in temporal bone trauma involving gunshot and blast injuries.[5] Exploration of the nerve in this setting is best performed utilizing a canal wall down mastoidectomy approach. As much of the nerve as possible should be explored by a surgeon experienced in surgical decompression of the entire facial nerve. Primary anastomosis is possible, particularly if the mastoid segment is involved. Tissue glues may be used to reapproximate the nerve intratemporally. However, the nerve is often transected with severe bony disruption and frequently there is loss of a segment of nerve as a result of the blast or secondary to thermal injury. In these cases, an interposition graft utilizing the great auricular or sural nerve may be necessary.

Facial Nerve Decompression

Surgical exploration of the facial nerve after temporal bone trauma requires the surgeon to be prepared for mastoid, translabyrinthine, and middle fossa exploration along with neural repair. While the ability to perform facial nerve decompression in theater is often beyond the scope of the general otolaryngologist, it is important to identify those patients who would benefit from this procedure to ensure timely referral and transport to a surgeon with this level of experience. Surgical decompression should be performed within 14 days of the injury, if possible, because this timeframe is associated with remarkably better recovery rates (>90%).[12] However, surgery may be delayed due to a variety of other concerns such as patient instability or other, more life-threatening injuries. Although the rate of recovery is not as high, if the decompression surgery is performed before 2 months after injury, it is generally associated with much better outcomes than when performed later.[12]

LOWER CRANIAL NERVES, IX THROUGH XII

The lower cranial nerves (IX, X, XI, and XII) are located in the posterior cranial fossa and exit the skull base through the jugular foramen and hypoglossal canal. Injury to these nerves in combat generally occurs by one of two mechanisms: penetrating neck injury (which may result in lacerations, avulsions, or completely severed nerves) or closed head injury with associated traumatic brain injury. The proximity of these nerves at the skull base frequently results in compound injuries, and many of these patients have complicated brain or carotid injuries resulting in high early mortality rates in patients with traumatic brain injury. One series quotes mortality rates with injury to the lower cranial nerves as high as 73.3%.[13]

Clinical manifestations of patients with lower cranial nerve injuries include dysphagia and velopharyngeal insufficiency (cranial nerves IX and X), shoulder weakness and pain (cranial nerve XI), and dysarthria and tongue deviation to the affected side in acute injuries (cranial nerve XII). As noted in the above section on evaluation of the facial nerve, these patients are often unconscious at the time of admission and are difficult to examine due to severe concomitant brain injury. Therefore, imaging is often necessary to diagnose these injuries, and 3-dimensional reconstruction can be useful for detecting fracture lines through the skull base and free bone fragments in proximity to the nerves.[13]

CRANIAL NERVE IX

The glossopharyngeal nerve supplies sensation to the tonsils, pharynx, and middle ear, and both sensation and taste to the posterior one-third of the tongue. Visceral sensory fibers are also received from the carotid body and sinus to sense the partial pressure of oxygen in the blood and pressure changes in arterial

blood, respectively. Parasympathetic fibers are transmitted from cranial nerve IX via the otic ganglion to the parotid gland. The only motor function of cranial nerve IX is to supply motor fibers to the stylopharyngeus muscle.

Isolated injury to this nerve is rare and may result in paroxysmal sharp pains in the throat, neck, or ear triggered by swallowing. Compression or entrapment of the ninth cranial nerve can result in symptoms similar to Eagle syndrome. While transection of this nerve is rarely documented in trauma, iatrogenic transection during resection of parapharyngeal space tumors generally results in minimal morbidity when only the glossopharyngeal nerve is affected.[14] There is no known role for primary neural repair if transection of the glossopharyngeal nerve is identified at the time of exploration, and attempts to isolate the nerve may result in injury to nearby lower cranial nerves at the skull base.

CRANIAL NERVE X

The paired vagus nerves descend from the brain through the jugular foramina and pass within the carotid sheath posterior and lateral to the common carotid artery. The right vagus nerve gives rise to the right recurrent laryngeal nerve (RLN), which passes around the right subclavian artery to run within the tracheoesophageal groove. It then descends into the chest posterior to the superior vena cava and right mainstem bronchus to provide innervation to the heart, lung, and esophagus. The left vagus nerve varies slightly as it gives rise to the left RLN, which passes around the aortic arch and ascends in the left tracheoesophageal groove.

The vagus nerve supplies parasympathetic fibers to all organs from the neck down to the second segment of the transverse colon, with the exception of the adrenal glands. The vagus nerve also supplies motor control to the intrinsic laryngeal muscles, pharyngeal constrictor muscles, cricothyroid, levator veli palatini, salpingopharyngeus, palatoglossus, and palatopharyngeus. It also provides 80% to 90% of the sensory innervation regarding the state of the viscera to the brain.[15]

Injury to the vagus nerve severely impacts laryngopharyngeal function. Injury at or above the skull base results in symptoms attributable to an RLN injury including hoarseness, stridor, and impaired cough, but also causes severe dysphagia and aspiration due to pharyngeal and palatal weakness and hypesthesia.[14]

Nonsurgical treatment measures include the use of a nasogastric tube for those at risk of aspiration. Alternatively, a gastrostomy should be considered in expected cases of prolonged dysfunction. Compensatory maneuvers are often helpful, and early consultation with a speech-language pathologist to provide swallow rehabilitation is important.[14,16]

Early surgical management of cranial nerve X injuries depends on the mechanism and location of the injury. In acute unilateral paralysis of the RLN, patients generally do not require adjunctive airway measures. However, patients with bilateral recurrent laryngeal nerve injury may present with stridor, requiring an emergent surgical airway with tracheotomy. Tracheotomy may also be required in patients with penetrating neck injuries who have other aerodigestive tract injuries.[17]

If the patient has a stable airway and is able to tolerate oral intake, early surgical intervention is not required. Spontaneous recovery of RLN function is possible after several months, and definitive surgery for vocal cord paralysis is usually delayed at least 6 to 12 months, unless the nerve is determined to be transected.[18]

More recent literature on patients with iatrogenic RLN injuries indicates that immediate exploration may result in improved voice outcomes in cases of neural transection of the RLN. In Rohde's series[19] of nine patients who underwent reconstruction with primary end-to-end anastomosis, free nerve graft, or vagus-RLN anastomosis, five patients rated their voice as normal or with only mild dysfunction. Seven of the nine patients had restoration of the vocal fold to the median physiologic phonating position with recovery of tension, mucosal wave, and glottic closure during phonation.[19]

A systematic review published in 2010 analyzed 14 studies describing laryngeal reinnervation procedures and outcomes. The most common technique was ansa cervicalis-to-RLN, although other techniques including primary anastomosis, ansa-to-thyroarytenoid, and hypoglossal-to-RLN were also reported. The greatest improvements in glottic gap were seen with ansa-to-RLN, and all studies demonstrated improvements in perceptual analysis and electromyography findings, regardless of technique. The study concluded that reinnervation is effective in the management of unilateral vocal fold paralysis.[20]

In a series of 29 patients with bilateral RLN palsies after thyroid and parathyroid surgeries, primary end-to-end anastomosis was performed in seven completely transected RLNs and four transected anterior RLN branches. Although none of the completely reconstructed nerves regained function, good muscle tone was observed.[21]

Restoring adductor motor function in the setting of unilateral vocal fold paralysis with complete or near-complete RLN transection can be achieved through medialization techniques or laryngeal reinnervation.

Potential advantages to reinnervation include more physiologic anatomy and mucosal wave function without the need for synthetic materials, maintenance of vocal fold bulk, and reversibility with the availability of static methods if reinnervation fails.[22] In the case of bilateral vocal fold paralysis, reinnervation of one or both posterior cricoarytenoid muscles may permit decannulation in patients with tracheotomies without requiring destructive procedures such as arytenoidectomy or cordotomy.[23] However, these measures are appropriate for delayed management and not recommended in the immediate postinjury period.

Acute reconstruction of RLN or superior laryngeal nerve injuries may be accomplished through end-to-end reanastomosis or cable grafting. Primary neurorrhaphy and cable grafting are the only methods that should be used acutely. While other methods such as direct implantation of a nerve ending into a muscle, the nerve-muscle pedicle technique, or muscle-nerve-muscle transplantation are possible, they are unlikely to be used acutely due to the complexity of the procedures and the difficulty assessing patient prognosis in the acute setting. Primary reinnervation is the simplest method, but requires adequate length in the remaining stumps of the RLN. While cable grafting is possible, axons are lost across each anastomotic site, making this method less effective.[24]

In conclusion, there are no prospective randomized studies available on RLN reconstruction, but there appears to be indication for immediate exploration and reconstruction of these nerves in some cases of transection. Additionally, immediate exploration may help determine the type of injury to the nerve, which can predict the likelihood of functional recovery. This knowledge can be used to guide future therapeutic management, including early versus delayed definitive management of vocal cord paralysis. However, immediate exploration should not delay transfer to a higher level of care from theater.

Injury due to skull base fractures is a separate entity from injury due to penetrating neck injuries. Skull base fractures may result in free bone fragments and hemorrhagic regions causing nerve compression. There is little evidence about decompression of the nerve in these types of injuries, but overall prognosis for this condition is poor. Early nerve decompression may be effective in the treatment of posttraumatic cranial nerve X injury caused by compression related to skull base fractures.[13,16]

CRANIAL NERVE XI

The spinal accessory nerve provides motor innervation to the sternocleidomastoid and trapezius muscles. Injury to this cranial nerve can result in pain, limited range of motion, and weakness of the ipsilateral shoulder and neck. Although experience with damage to cranial nerve XI is frequently iatrogenic, the nerve is vulnerable to blunt or penetrating injuries to the neck or fractures involving the jugular foramen. Physiotherapy is generally considered as the standard treatment; however, surgery has been discussed as an option. If surgical intervention is recommended, it is generally performed in a delayed fashion for symptomatic patients, with the best outcomes thought to occur when surgery is performed within a few months of injury.[25,26] Neurolysis, primary repair, and nerve grafting have been used to rehabilitate those with complete paralysis of the spinal accessory nerve, with good results up to 1 year or more after initial injury.[25,27–29] Although there is little evidence to support the use of immediate repair at the time of injury, authors who advocate early operative intervention cite superior functional results compared to conservative therapy.[26,29,30] If wound exploration is undertaken and the severed nerve is identified, it is reasonable to attempt primary repair or tag the terminal ends for ease in identification at a later date. If attempted, repair of the nerve should be performed using magnification, microinstrumentation, and microsutures of 9-0 or 10-0 nylon or polypropylene. A tension-free repair is critical to success, and interpositional grafting should be used when tension-free primary anastomosis is not possible.[31]

When repair is performed, the proximal and distal free nerve endings should be cleanly cut with a scalpel or micro-scissor. A single-interrupted epineural suture is loosely placed to reapproximate the ends. Subsequent interrupted sutures are placed in a similar fashion, taking care to avoid tight approximation, which can lead to misdirected fibers. Mobilization of the cut ends less than 2 cm can prevent tension without devascularizing the nerve.[32]

CRANIAL NERVE XII

The hypoglossal nerve arises from the medulla oblongata and passes through the hypoglossal canal, exiting the skull base medial to the jugular foramen. It then passes behind the vagus nerve and between the internal carotid artery and internal jugular vein. The nerve then passes deep to the posterior belly of the digastric muscle and then medially to innervate the tongue.

The hypoglossal nerve provides the motor supply to all of the muscles of the tongue with the exception of the palatoglossus, which is innervated by the vagus nerve. Because of the tongue's role in swallowing and speech, injury to this nerve may result in dysarthria and dysphagia. On physical examination, the tongue will protrude toward the affected side and, later, the patient may show ipsilateral tongue atrophy and fasciculations.[18,33]

Isolated hypoglossal nerve injuries without severe great vessel or other lower cranial nerve injuries are rare.[34] Future rehabilitation with swallowing and speech therapy may help patients with other unstable injuries.[18] Hypoglossal nerve injuries caused by penetrating wounds reportedly respond relatively well to surgical interventions.[33]

Avitia and Osborne[35] reported on the successful early repair of an iatrogenic hypoglossal nerve injury. After identification and mobilization of the terminal ends of the nerve, a tension-free anastomosis was performed under magnification with 8-0 polypropylene suture. The patient recovered oral competence, improved speech, and maintained muscle mass of the ipsilateral tongue. Messner's case report of two patients with bilateral traumatic hypoglossal nerve injuries repaired using greater auricular nerve grafts also reported preserved tongue muscle bulk and tone, but the patients had only minimal restoration of voluntary motor function.[36] Another case of traumatic bilateral hypoglossal nerve injury was reported with later repair, at 6 and 8 months postinjury. The patient had normal electromyographic studies at the 11-year follow-up, but did not recover speech, mastication, and swallowing despite prolonged physical therapy, suggesting a role for early intervention.[34]

In summary, early repair of the transected hypoglossal nerve in a hemodynamically stable patient may be indicated for the restoration of tongue bulk and tone, but the functional improvement of early hypoglossal nerve repair is unknown.

SUMMARY

It is important to note that the presence of cranial nerve injuries is frequently discovered many days after the injury. In particular, facial nerve evaluation and repair is often delayed because of other, life-threatening injuries or because the patient is obtunded and there is no adequate way to access facial function at the time of presentation. Ideally, the trauma team should perform a quick assessment of the facial nerve during the neurologic survey at initial presentation for any patient at risk. Surgery should be performed as expeditiously as possible because delays increase the likelihood of fibroma formation and scarring.

High-dose systemic steroid therapy for traumatic facial paralysis may be considered. However, there is conflicting evidence as to its efficacy. Steroids improve functional recovery when administered in the immediate period following neurorrhaphy in animal models.[37] In crush injuries in juvenile mice, there was a trend toward increased functional recovery with the administration of corticosteroids, although in adult mice steroids were shown to inhibit recovery.[38] In general, despite the lack of definitive evidence, administration of corticosteroids is often recommended for cases of blunt trauma where no exploration has been performed or there is evidence of significant edema upon exploration.

It is also important to remember that any function of the facial and other cranial nerves will not begin to be recovered until approximately 6 to 12 months after repair, with more proximal injuries taking longer to recover.[39] If there has been no sign of recovery by 12 months, there is very little chance of any further improvement of function.

Injuries to the lower cranial nerves are often associated with other severe and potentially life-threatening injuries. Most of the time these nerves are not damaged in isolation, and multiple cranial nerves may be involved, along with injuries to the major vessels of the neck, skull base, and airway. It is difficult in these often unstable patients to accomplish primary repair of these nerves in the acute setting. In the case of recurrent laryngeal nerve injury, outcomes are difficult to predict, and delayed management either with phonosurgery or reinnervation procedures is very reasonable. Symptomatic treatment and airway protection should be addressed in the acute setting. Early nutritional support via nasogastric tube or gastrostomy should also be considered.

Although the acute management of these injuries is important, the treatment and rehabilitation of cranial nerve injuries is a continuous process that may take many months to years. Not uncommonly, difficulties associated with these injuries may last a lifetime. Therefore, it is imperative to have close follow up and detailed communication with the next role of care. Patients should be referred to a team of surgeons and ancillary providers such as speech pathologists and physical therapists with experience in the long-term management of cranial nerve injuries.

CASE PRESENTATIONS

Case Study 18-1

Presentation

A middle-aged Iraqi male presented to the emergency room with penetrating facial trauma from a rocket-propelled grenade. The patient was alert and oriented and his initial vital signs were stable. He had a small, 2-cm laceration anterior to the left angle of the mandible (Figure 18-1). He had complete paralysis in his lower facial nerve branches, but his temporal branch was intact. Examination of the ears revealed no abnormalities or signs of trauma.

Preoperative Workup/Radiology

Plain films of the face revealed a radiopaque foreign body within the soft tissues overlying the left mandibular ramus. No other testing was performed.

Operative Plan/Timing of Surgery

The patient was taken to the operating room within 24 hours for exploration and possible facial nerve repair.

Operation

The patient was intubated without complication. During exploration, the existing laceration was connected to a small infraauricular incision. The wound was explored superficially and a large (2.5-cm) piece of fragment was easily identified and removed (Figures 18-2 and 18-3). The main branch of the facial nerve was then identified and dissected free from the parotid tissue. All branches were identified, and a contusion with edema of the lower division was noted. Since the nerve was intact, no primary repair was performed. The wound was irrigated, suctioned free, and closed in layers after nonviable tissue was debrided. Intravenous corticosteroids were administered perioperatively.

Figure 18-1. Laceration near the left angle of mandible resulting from a fragment injury.

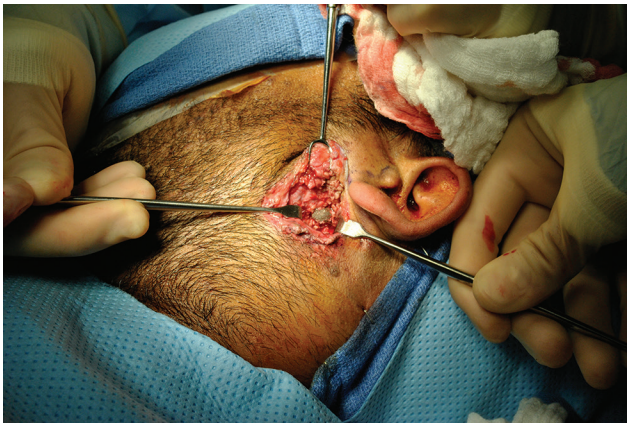

Figure 18-2. Fragment discovered in the wound during exploration.

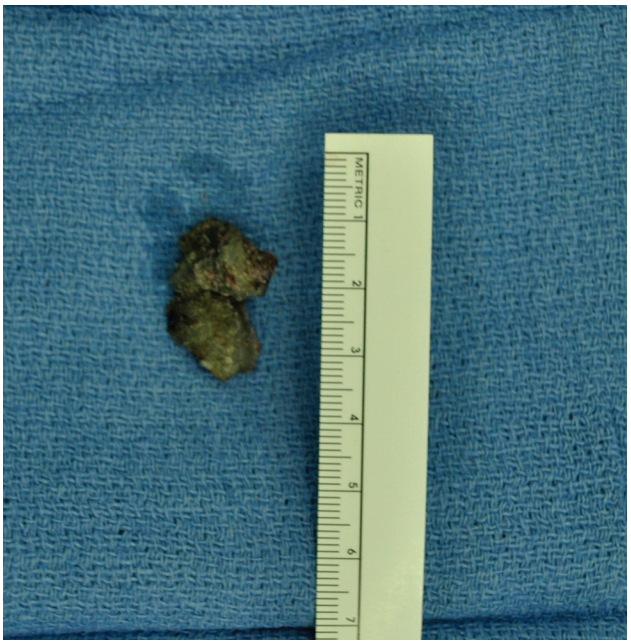

Figure 18-3. The fragment from Figure 18-3 removed.

Complications

None.

Lessons Learned

Although the patient had no movement in the branches of his lower division, the nerve was intact and not transected, which suggests a good prognosis for at least some recovery of facial function. Nerve exploration of any patient with immediate onset paralysis is recommended because it assists in determining prognosis and allows for definitive treatment in the acute setting. Unfortunately, because the patient was an Iraqi national, he was lost to follow-up shortly after surgery. No long-term evaluation of his facial nerve function could be performed.

Case Study 18-2

Presentation

A middle-aged male member of the Afghan National Police was transferred for management of a tracheal injury and left mastoid injury following a gunshot wound to the left side of the head and chest. Prior to transfer, he was noted by the first responders to have a facial paralysis (House-Brackmann grade VI) on the left side (Figure 18-4) associated with a postauricular gunshot entry wound.

Figure 18-4. Patient with complete (House-Brackmann grade VI) left facial nerve paralysis.

Preoperative Workup/Radiology

The patient's tracheal injury was first addressed by the cardiothoracic surgeon and required a thoracotomy and tracheotomy. After stabilization and when he was no longer sedated, a full facial evaluation was performed, which confirmed a total left-sided facial paralysis. Fine-cut CT imaging of the temporal bones revealed a projectile trajectory from the left mastoid through the Eustachian tube and into the nasopharynx. Although the pathway appeared radiographically to be immediately adjacent to the facial nerve, there appeared to be no transection. Audiologic testing was not available, but the Weber test lateralized to the contralateral ear, and a severe sensorineural hearing loss was suspected. Since radiographic imaging demonstrated no otic capsule involvement, the hearing loss was thought to be secondary to a concussive effect. He was empirically treated with dexamethasone 8 mg three times a day for 3 days with a subsequent rapid taper.

Operative Plan/Timing of Surgery

Evaluation and management of the patient's facial paralysis was deferred until after his potentially life-threatening thoracic injuries were addressed. As

Figure 18-5. Axial computed tomography scan showing bullet entry wound and trajectory (*black arrow*) through the left mastoid and metallic fragments within the nasal cavity (*white arrows*).

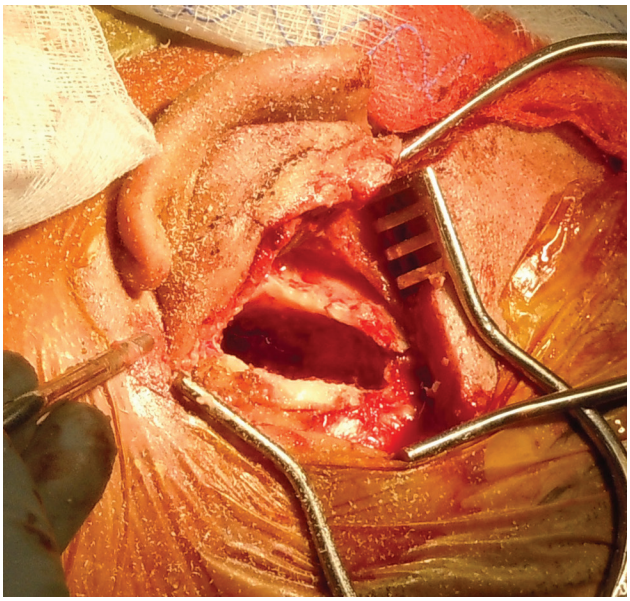

Figure 18-6. Intraoperative view of left mastoid entry wound (enlarged with drill).

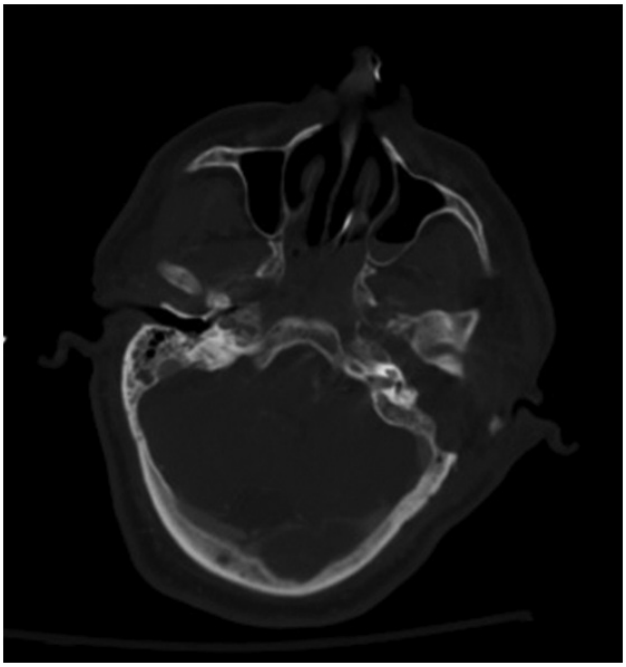

Figure 18-7. Postoperative imaging with obliterated mastoid cavity.

previously described, the facial nerve appeared anatomically intact on imaging, and bony and soft tissue density fragments were noted within the mastoid and middle ear space (Figure 18-5). Presuming the soft tissue densities within the mastoid contained epithelial components, and due to concern that the patient would not have access to follow-up care, the decision was made to perform a canal wall down mastoidectomy with debridement of epithelial and bony fragments. In addition, much of the injury appeared to be intratemporal. Therefore, it was decided to perform a selective decompression of the tympanic and mastoid segments of the facial nerve.

Operation

The mastoid surgery was performed approximately 10 days after the tracheal repair. The patient's entry wound was incorporated into a postauricular incision (Figure 18-6). A canal wall down mastoidectomy and debridement of nonviable tissue surrounding the bullet's trajectory were performed. The facial nerve was subsequently decompressed at the tympanic and mastoid segments; the labyrinthine, geniculate, and meatal segments were not decompressed. The decision to perform a limited decompression of the tympanic and mastoid segments was based on several factors: the location of the injury, the magnification limitations of the available operating microscope, a desire to avoid intracranial exposure, and an attempt to provide the most benefit with the least morbidity. The facial nerve was found to be intact in the decompressed segments. The mastoid cavity was then obliterated with fat, and the Eustachian tube was occluded with wax, Surgicel (Ethicon Inc, West Somerville, NJ), and temporalis fascia. The external auditory canal was then oversewn. A postoperative CT was performed (Figure 18-7) demonstrating successful mastoid obliteration.

Complications

None.

Lessons Learned

Because the patient was an Afghan national, he was not eligible for evacuation to a higher role of care for definitive treatment. Surgical management in theater was performed because he would have no options for definitive treatment once released. The decision to operate was made predominantly on a desire to decrease the risk of late wound complications and cholesteatoma formation and not primarily because of the facial paralysis. The patient was lost to follow-up shortly after surgery and no long-term evaluation of his facial nerve function could be performed. Despite a complete and sudden paralysis, the nerve was fully intact along the decompressed portions based on imaging and intraoperative findings. Without long-term follow up it is impossible

to comment on this particular patient's eventual outcome. However, since the nerve was found to be anatomically intact, his prognosis was expected to be better than if the nerve were transected. Exploratory findings can give the counseling provider prognostic information regarding future facial nerve function that can be communicated to a patient with limited or no follow-up.

REFERENCES

1. Meyer RA, Bagheri SC. Microsurgical reconstruction of the trigeminal nerve. *Oral Maxillofac Surg Clin North Am*. 2013;25(2):287–302.

2. Chan RK, Siller-Jackson A, Verrett AJ, Wu J, Hale RG. Ten years of war: a characterization of craniomaxillofacial injuries incurred during operations Enduring Freedom and Iraqi Freedom. *J Trauma Acute Care Surg.* 2012;73(6 Suppl 5):S453–S458.

3. Darrouzet V, Duclos JY, Liguoro D, Truilhe Y, De Bonfils C, Bebear JP. Management of facial paralysis resulting from temporal bone fractures: our experience in 115 cases. *Otolaryngol Head Neck Surg*. 2001;125:77–84.

4. House JW, Brackmann DE. Facial nerve grading system. *Otolaryngol Head Neck Surg*. 1985;93:146–147.

5. Bento RF, de Brito RV. Gunshot wounds to the facial nerve. *Otol Neurotol*. 2004;25(6):1009–1013.

6. Fisch U. Maximal nerve excitability testing vs. electroneuronography. *Arch Otolaryngol Head Neck Surg*. 1980;106:352.

7. Sittel C, Stennert E. Prognostic value of electromyography in acute peripheral facial nerve palsy. *Otol Neurotol*. 2001;22:100–104.

8. Danner CJ. Facial nerve paralysis. Otolaryngol *Clin North Am*. 2008;41(3):619–632.

9. Kollewe K, Mohammadi B, Dengler R, Dressler D. Hemifacial spasm and re-innervation synkinesias: long-term treatment with either Botox or Dysport. *J Neural Transm*. 2010;117(6):759–763.

10. Telischi FF, Patete ML. Blast injuries to the facial nerve. *Otolaryngol Head Neck Surg*. 1994;111(4):446–449.

11. Humphrey CD, Kriet JD. Nerve repair and cable grafting for facial paralysis. *Facial Plast Surg*. 2008;24(2):170–176.

12. Hato N, Nota J, Hakuba N, Gyo K, Yanagihara N. Facial nerve decompression surgery in patients with temporal bone trauma: analysis of 66 cases. *J Trauma*. 2011;71(6):1789–1792.

13. Jin H, Wang S, Hou L, et al. Clinical treatment of traumatic brain injury complicated by cranial nerve injury. *Injury*. 2010;41:918–923.

14. Eibling DE, Boyd EM. Rehabilitation of lower cranial nerve deficits. *Otolaryngol Clin North Am*. 1997;30(5):865–875.

15. Berthoud HR, Neuhuber WL. Functional and chemical anatomy of the afferent vagal system. *Auton Neurosci.* 2000;85:1–17.

16. Legros B, Fournier P, Chiaroni P, et al. Basal fracture of the skull and lower (IX, X, XI, XII) cranial nerves palsy: four case reports including two fractures of the occipital condyle—a literature review. *J Trauma*. 2000;48(2):342–348.

17. Bumpous JM, Whitt PD, Ganzel TM, McClane SD. Penetrating injuries of the visceral compartment of the neck. *Am J Otolaryngol*. 2000;21(3):190–194.

18. Marentette LJ, Goding GS Jr, Levine SC. Rehabilitation of the lower cranial nerves. *Neurosurg Clin North Am*. 1993;4(3):573–580.

19. Rohde SL, Wright CT, Muckala JC, Wiggleton J, Rousseau B, Netterville JL. Voice quality after recurrent laryngeal nerve resection and immediate reconstruction. *Otolaryngol Head Neck Surg*. 2012;147(4):733–736.

20. Aynehchi BB, McCoul ED, Sundaram K. Systematic review of laryngeal reinnervation techniques. *Otolaryngol Head Neck Surg*. 2010;143(6):749–759.

21. Crumley RL. Update: ansa cervicalis to recurrent laryngeal nerve anastomosis for unilateral laryngeal paralysis. *Laryngoscope*. 1991;101(4):384–388.

22. Crumley RL. Teflon versus thyroplasty versus nerve transfer: a comparison. *Ann Otol Rhinol Laryngol*. 1990;99(10):759–763.

23. Paniello RC. Laryngeal reinnervation. *Otolaryngol Clin North Am*. 2004;37(1):161–181.

24. Paniello RC, West SE, Lee P. Laryngeal reinnervation with the hypoglossal nerve. I. Physiology, histochemistry, electromyography, and retrograde labeling in a canine model. *Ann Otol Rhinol Laryngol*. 2001;110:532–542.

25. Kim DH, Cho YJ, Tiel RL, et al. Surgical outcomes of 111 spinal accessory nerve injuries. *Neurosurgery*. 2003;53(5):1106–1112.

26. Chandawarkar RY, Cervino AL, Pennington GA. Management of iatrogenic injury to the spinal accessory nerve. *Plast Reconstr Surg*. 2003;111(2):611–617.

27. Ogino T, Sugawara M, Minami A, Kato H, Ohnishi N. Accessory nerve injury: conservative or surgical treatment? *J Hand Surg Br*. 1991;16(5):531–536.

28. Nakamichi K, Tachibana S. Iatrogenic injury of the spinal accessory nerve. Results of repair. *J Bone Joint Surg Am*. 1998;80(11):1616–1621.

29. Weisberger EC, Kincaid J, Riteris J. Cable grafting of the spinal accessory nerve after radical neck dissection. *Arch Otolaryngol Head Neck Surg*. 1998;124(4):377–380.

30. Osgaard O, Eskesen V, Rosenørn J. Microsurgical repair of iatrogenic accessory nerve lesions in the posterior triangle of the neck. *Acta Chir Scand*. 1987;153(3):171–173.

31. Dvali L, Mackinnon S. Nerve repair, grafting, and nerve transfers. *Clin Plast Surg*. 2003;30(2):203–221.

32. Maki Y, Firrell JC, Breidenbach WC. Blood flow in mobilized nerves: results in a rabbit sciatic nerve model. *Plast Reconstr Surg*. 1997;100(3):627–633.

33. Hammond FM, Masel BE. Chapter 30: Cranial Nerve Disorders. In: Zasler ND, Katz DI, Zafonte RD, eds. *Brain Injury Medicine—Principles and Practice*. New York, NY: Demos; 2007.

34. Shahzadi S, Abouzari M, Rashidi A. Bilateral traumatic hypoglossal nerve transection in a blast injury. *Surg Neurol*. 2007;68(4):464–465.

35. Avitia S, Osborne RF. Surgical management of iatrogenic hypoglossal nerve injury. *Ear Nose Throat J*. 2008;87(12):672–676.

36. Messner AH, McGuirt WF, Blalock D. Bilateral hypoglossal nerve transection. *Otolaryngol Head Neck Surg*. 1995;112(2):329–332.

37. Seth R, Revenaugh PC, Kaltenbach JA, et al. Facial nerve neurorrhaphy and the effects of glucocorticoids in a rat model. *Otolaryngol Head Neck Surg*. 2012;147(5):832–840.

38. Lieberman DM, Jan TA, Ahmad SO, Most SP. Effects of corticosteroids on functional recovery and neuron survival after facial nerve injury in mice. *Arch Facial Plast Surg*. 2011;13(2):117–124.

39. Eaton DA, Hirsch BE, Mansour OI. Recovery of facial nerve function after repair or grafting: our experience with 24 patients. *Am J Otolaryngol*. 2007;28(1):37–41.