Chapter 21

DENVER VETERANS AFFAIRS MEDICAL CENTER EXPERIENCE WITH POSTDEPLOYMENT DYSPNEA CASE REPORTS

CAROLYN H. WELSH, MD*; AND YORK E. MILLER, MD†

INTRODUCTION

CASE 1

CASE 2

SERIES OF BIOPSIES

SUMMARY

*Professor, Department of Medicine, Division of Pulmonary Sciences and Critical Care Medicine, University of Colorado Denver School of Medicine, Anschutz Medical Campus, 12700 East 19th Avenue, Aurora, Colorado 80045; Staff Physician and Sleep Program Director, Denver Veterans Affairs Medical Center, Eastern Colorado Health Care System, 1055 Clermont Street, Denver, Colorado 80220

†Thomas L. Petty Chair of Lung Research Professor, Department of Medicine, Division of Pulmonary Sciences and Critical Care Medicine, University of Colorado School of Medicine, Anschutz Medical Campus, 12700 East 19th Avenue, Aurora, Colorado 80045; Staff Physician and Chest Clinic Director, Denver Veterans Affairs Medical Center, Eastern Colorado Health Care System, 1055 Clermont Street, Denver, Colorado 80220

INTRODUCTION

Patients without symptoms prior to deployment to southwest Asia have experienced respiratory symptoms, exercise difficulty, and even impaired ability to perform basic activities of daily living after return from one or more tours of duty. A larger number of soldiers deployed to Iraq and Afghanistan are reported to have respiratory symptoms compared with soldiers deployed to other locations (14.5% vs 1.8%).[1] One series of exposed individuals reports respiratory symptoms and findings of constrictive bronchiolitis.[2] Of note, not all of these persons have a history of tobacco smoking. Although the majority of people returning stateside experience no respiratory impairment, there are a growing number of instances in which chronic, otherwise unexplained shortness of breath and cough accompany a significant alteration in exercise capacity and ability to carry out activities of daily living. Two illustrative cases are presented herein with findings that, after diagnostic workup, were not attributable to asthma or chronic obstructive pulmonary disease and showed persistence of findings on serial assessments.

CASE 1

A 36-year-old man presented in 2010 with dyspnea on exertion and productive cough. His symptoms began in 2002 while he was deployed to Bagram Airfield in Afghanistan. At that time, he had wheezing and the onset of dark, sometimes black sputum. He was told that he had smoking-related lung disease although he never smoked. While in Tikrit, Iraq, for 12 months during 2005 to 2006, he experienced dyspnea on exertion and could barely run 1½ to 2 miles. He would become lightheaded and stopped running so he would not pass out. His run time increased to 17 minutes for a 2-mile run. He lived ¼ mile from pits where trash was burned and was assigned to work in demining operations. At this time, there was an uncapped oil well burning 1 mile out of town. From 2007 to 2008, he was again in Afghanistan for 12 months. He worked in an old Russian crematorium and had contact with human remains. He also had direct contact with asbestos-wrapped pipes. Over these three separate deployments, his symptoms resolved, but never normalized with stateside return.

In his permanent residence, there were no birds, hot tub, or water damage in his home. He was a clerical worker. After his third return stateside, his running distance had decreased markedly.

On examination, he was a well-groomed man without use of accessory muscles to breathe. Pulse was elevated at 113, and blood pressure was 138/98 mm Hg. His body mass index was borderline high at 26.3. He had no lymphadenopathy and no adventitious breath sounds. On cardiac examination, there was no jugular venous distention, and heart sounds were normal without murmurs. Abdominal examination was normal, and extremities were without edema. Pulse oximetry showed 94% saturation at rest, normal at an altitude of 5,280 feet. While

TABLE 21-1

CASE 1: PULMONARY FUNCTION TESTING

	June 2010	May 2011	July 2012
FVC (L)	4.13 (84%)	4.03 (73%)	3.89 (70%)
FEV_1 (L)	3.63 (89%)	3.53 (80%)	3.22(73%)
FEV_1/FVC ratio	0.88	0.88	0.83
TGV (L)	1.79 (50%)	1.89 (53%)	2.01 (56%)
RV (L)	1.13 (62%)	1.39 (74%)	1.43 (76%)
TLC (L)	5.25 (74%)	5.46 (76%)	5.40 (75%)
DLCO/VA (mL/min/mm Hg)	112%	129%	121
Bronchodilator response	No	No	13%

DLCO/VA: diffusing capacity of the lung for carbon monoxide corrected for alveolar volume; FEV_1: forced expiratory volume in 1 second; FVC: forced vital capacity; RV: residual volume; TGV: thoracic gas volume performed by plethysmography; TLC: total lung capacity
Note: Serial pulmonary function testing. Percentages are percent predicted for gender, ethnicity, weight, and height.

running, his oxygen saturations dropped to 82%. Serial pulmonary function is shown in Table 21-1. There was a mild restrictive process without improvement over a 2-year interval.

Transthoracic echocardiograph was normal, and chest X-ray film was normal. Thoracic computed tomography scans in 2010 and 2011 showed no interstitial lung changes, airspace opacity, or mosaicism. On polysomnography, the apnea hypopnea index was mildly elevated at 6.

Lung biopsy showed nonspecific changes of hyperinflation, with mild patchy bronchiolar and peribronchiolar chronic inflammation and minimal focal cellular bronchiolitis. There was mild patchy peribronchiolar mixed dust and anthracotic pigment with pigmented macrophages in airspaces (Figure 21-1).

For his airway symptoms, he had been treated with inhaled corticosteroids, prednisone, sodium mycophenolate, and azithromycin with minimal response in dyspnea or exercise distance. He is currently using a budesonide/formoterol inhaler and azithromycin three times weekly. He notes continued dyspnea and hypoxemia when he exercises.

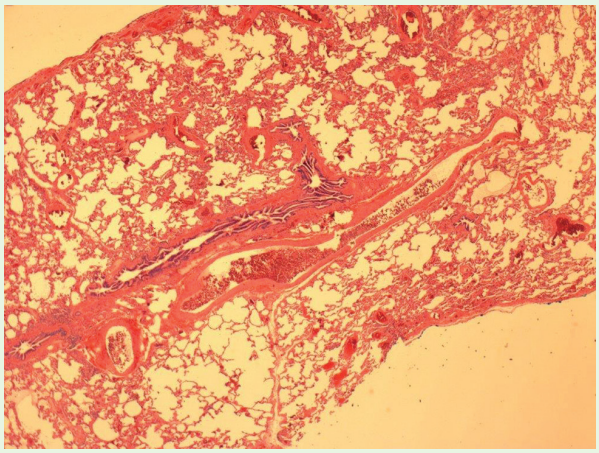

Figure 21-1. Representative areas of peribronchiolar inflammation and mild cellular bronchiolitis from lung biopsy. Hematoxylin and eosin stain, Case 1.

CASE 2

A 37-year-old man presented with pulmonary evaluation in early 2011. He noted shortness of breath while putting on socks, showering, and walking 25 feet. He was no longer able to perform his job driving a truck for a scrapyard because of coughing and shortness of breath. His wife described the onset of his trouble breathing in 2007, 4 years prior to presentation. He was short of breath when he laid flat; therefore, he slept in a recliner.

He coughed when he was supine and then regurgitated. He noted sharp anterior chest pain when he inspired. Seven years previously, he could run 2 miles in 15 minutes. He smoked briefly at age 14 for less than 1 year and has been a nonsmoker since that time.

He was deployed to Tikrit, Iraq, for 4 months in 2003. He had a second deployment of 12 months starting November 2005 in Baqubah, Iraq. During this time, he lived 2 miles

TABLE 21-2

CASE 2: PULMONARY FUNCTION TESTING

	April 2011	June 2011	April 2012
FVC (L)	4.58 (71%)	4.50 (70%)	3.29 (51%)
FEV_1 (L)	3.40 (66%)	3.63 (71%)	2.80 (50%)
Ratio FEV_1/FVC	0.74	0.81	0.85
TGV (L)	2.69 (64%)	3.43 (82%)	2.49 (59%)
RV (L)	1.54 (73%)	3.26 (155%)	2.21 (104%)
TLC (L)	7.36 (90%)	5.20 (64%)	6.29 (77%)
DLCO/VA (mL/min/mm Hg)	98%	—	108%
Bronchodilator response	33%	—	17%
MIP/MEP		44%/30%	

DLCO/VA: diffusing capacity of the lung for carbon monoxide corrected for alveolar volume; FEV_1: forced expiratory volume in 1 second; FVC: forced vital capacity; MEP: maximum expiratory pressure; MIP: maximum inspiratory pressure; RV: residual volume; TGV: thoracic gas volume performed by plethysmography; TLC: total lung capacity

Note: Serial pulmonary function testing. Percentages are percent predicted for gender, ethnicity, weight, and height. Dashes indicate that no test was performed and that data are not available.

downwind of the burn pits. He had nightly pesticide mist exposure. He took two platoons worth of trash to the burn pits every day, and these were often downwind. He worked on wash detail. During deployment, there were frequent dust storms.

On examination, blood pressure was 119/64 mm Hg, pulse was 62, and body mass index was 32. He was not using accessory muscles to breathe and had no rash. He had no lymphadenopathy or jugular venous distention. There was good air movement with mild inspiratory crackles at the bases that cleared with coughing. He had a shallow breathing pattern. Cardiac examination showed a normal S1, S2 and no murmurs or gallops. He had no pedal edema. Oxygen saturation was normal (96% on room air at rest, 95% with exertion). Serial pulmonary function is shown in Table 21-2. He had intermittent airflow limitation with a bronchodilator response and hyperinflation. He also had low thoracic gas volume, a restrictive finding that had not resolved over a 1-year interval.

The computed tomography scan of the thorax showed no consolidation, nor any abnormal findings (including ground-glass attenuation, interlobular septal thickening, subpleural reticular abnormalities, diffuse parenchymal nodularity, significant bronchiectasis, or evidence of pulmonary fibrosis).

Extensive diagnostic workup included lack of diaphragmatic paresis on sniff test and normal vocal cord movement with no vocal cord dysfunction on laryngoscopy. In addition, he had a normal apnea hypopnea index on an in-laboratory sleep study. His 6-minute walk test at 3 L/min with resting oxygen saturation was 94%, with a heart rate of 102 beats/min. Posttest oxygen saturation was 97%, and heart rate was 99 beats/min. The Borg Dyspnea Scale score was 4 (somewhat heavy), with a walking distance of only 500 feet in 6 minutes on 3 L/min of oxygen (using a cane).

Lung biopsy showed hyperinflated lung parenchyma. There was a subacute bronchiolocentric process characterized by chronic inflammation with occasional poorly formed granulomas and scattered giant cells. Changes appeared to be more prominent in lower and middle lobe sections (Figure 21-2). No fibrosis, constrictive bronchiolitis, or polarizable material was seen, and the pathologist's conclusion was inflammation that appeared most compatible with a process of subacute hypersensitivity pneumonitis.

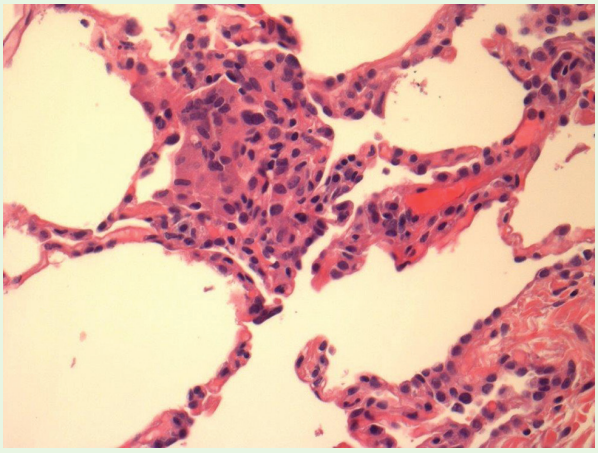

Figure 21-2. High power view of chronic inflammation area. Poorly formed giant cells were noted in other areas of the lung biopsy specimen. Hematoxylin and eosin stain, Case 2.

His treatment included inhaled mometasone, formoterol, and albuterol as needed up to 8 times daily. Tiotropium had been subsequently added. He received two courses of high-dose prednisone tapering over 2 weeks. Despite this, he had progressive worsening of symptoms such that he could no longer function in his job.

SERIES OF BIOPSIES

In our practice group, there have been more than 40 patients referred for persistent airway symptoms after deployment to southwest Asia. Of these, eight patients underwent thoracoscopic lung biopsies after careful review of their unexplained symptoms. All cases are discussed in a multidisciplinary conference with imaging, surgery, and pulmonology input prior to referral for this procedure.

Although the symptoms and time course for these patients were not classic for asthma, most were tried on bronchodilator therapy without clinical response prior to referral for biopsy. Specimens of these eight patients were reviewed by a pathologist with expertise in pulmonary pathology. Findings include comments on hyperinflation for five of the eight specimens. Assessments include the following:

- sarcoid,
- perivascular nonnecrotizing granulomas,
- constrictive bronchiolitis,
- multiple chemodectomas,
- focal cellular bronchiolitis,
- patchy lymphocytic respiratory bronchiolitis, and
- two cases with bronchocentric granulomas.

None of the specimens showed normal lung tissue.

SUMMARY

These are two illustrative cases of unanticipated dyspnea and respiratory symptoms after deployment to southwest Asia. Findings are not fully explained by a diagnosis of asthma or chronic obstructive pulmonary disease, although Case 2 has had intermittent hyperinflation and clear bronchodilator responses on two occasions. Neither patient has smoked tobacco for more than a minimal exposure. Both of these cases have experienced a dramatic drop in their functional activity and have not improved over time. Pathological findings include abnormalities in the bronchiolar and bronchial regions of the specimens, and radiographic abnormalities are not evident. Pulmonary function shows restrictive features for Case 1 and intermittent obstruction with a low thoracic gas volume, also a restrictive finding, in Case 2. Symptoms and findings in Case 2 have progressed long after his time of deployment, and both men have experienced life-altering symptoms.

This chapter notes findings for two persons and is not a comprehensive assessment of persons deployed to Afghanistan and Iraq. It does, however, illustrate that for some people there is a persistent process other than asthma with restrictive features on physiology for which treatment is unclear and prognosis not defined. Fortunately, the majority of persons do not experience such symptoms after deployment; however, referrals are common enough to warrant concern. That these pulmonary abnormalities in exposed persons do not affect the majority of those exposed is parallel to the symptom incidence in other exposures causing bronchial and interstitial diseases (eg, beryllium workers). In one series of chronic beryllium disease, only 4% of exposed workers develop clinical disease.[3] Further assessment of risk, exposures, and natural history as outlined in the working group document is warranted.[4]

REFERENCES

1. Szema AM, Salihi W, Savary K, Chen JJ. Respiratory symptoms necessitating spirometry among soldiers with Iraq/Afghanistan war lung injury. *J Occup Environ Med*. 2011;53:961–965.

2. King MS, Eisenberg R, Newman JH, et al. Constrictive bronchiolitis in soldiers returning from Iraq and Afghanistan. *N Engl J Med*. 2011;365:222–230.

3. Schuler CR, Kent MS, Deubner DC, et al. Process-related risk of beryllium sensitization and disease in a copper-beryllium alloy facility. *Am J Ind Med*. 2005;47:195–205.

4. Rose C, Abraham J, Harkins D, et al. Overview and recommendations for medical screening and diagnostic evaluation for postdeployment lung disease in returning US warfighters. *J Occup Environ Med*. 2012;54:746–751.