

Pelvic Injuries

Introduction

- Injuries of the pelvis are an uncommon, but potentially lethal battlefield injury.
- Blunt injuries may be associated with major hemorrhage and early mortality. Death within the first 24 hours of injury in these patients is most often due to hemorrhage. Civilian mortality rates have ranged from 18% to 40%.
- Penetrating injuries to the skeletal pelvis are usually associated with abdominopelvic organ injury.
- Key issues in the management of pelvic fractures are to identify if the patient is hemodynamically stable and if the pelvic fracture is mechanically stable.
 - If the patient is not hemodynamically stable, it is imperative to identify all sites of hemorrhage, because pelvic fractures often occur in conjunction with other life-threatening injuries.
 - Appropriate evaluation of the abdomen, chest, and other potential sites of injury and hemorrhage cannot be overstressed.
- Additionally, a thorough examination of the pelvis and perineum is required to rule out associated injuries to the rectum and genitourinary / gynecological systems, which may render the fracture open.
- Open injuries require early recognition and prompt treatment to prevent high mortality due to early hemorrhage and late sepsis. The mortality rate of open pelvic fractures is >50%.
- **Diagnosis.**
 - Leg-length discrepancy, scrotal or labial swelling / echymosis, or abrasions over the pelvis raise suspicion for pelvic ring injury.

- The perineum, rectum, and vaginal vault must be evaluated for lacerations to rule out an open injury.
- Assess pelvic stability by applying a posteriorly directed force to the iliac crests at the level of the anterior superior iliac spine. If the symphysis opens >2.5 cm, or the hemipelvis shifts posteriorly, the pelvis is unstable. This examination should be completed only once by the most experienced provider available, because additional manipulation can exacerbate hemorrhaging.

Bladder and urethral injuries are suspected when blood is present at the meatus or in the urine, or when a Foley catheter cannot be passed. Retrograde urethrogram and cystography confirm the diagnosis.

- Radiographs (anterior-posterior pelvis and, when possible, inlet and outlet views) confirm the diagnosis. CT defines the location and extent of injury more accurately, but is not necessary in the immediate evaluation of these patients.

Blunt Injuries

- Patterns and mechanisms are the same as those seen in civilian blunt trauma.
 - Lateral compression injuries are marked by internal rotation or midline displacement of the hemipelvis. By definition, these injuries maintain an intact pelvic floor and are at least partially stable. Radiographic hallmarks include oblique ramus fractures anteriorly and vertically congruent sacroiliac joints posteriorly. Closed-head injuries are associated with this mechanism. Generally, these injuries infrequently require significant transfusion.
 - Vertical shear injuries have cephalad displacement of the hemipelvis and are mechanically unstable. Radiographic hallmarks include a widened symphysis or vertical ramus fractures anteriorly and a vertically disrupted sacroiliac joint posteriorly. These injuries have a high incidence of retroperitoneal hematoma formation and consumptive coagulopathy. These injuries have a predilection for hemorrhage and may require significant transfusion of blood and blood products for resuscitation.

- Anterior-posterior (open book) injuries demonstrate external rotation of the hemipelvis. Radiographic hallmarks include a widened symphysis or vertical ramus fractures anteriorly and wide but vertically congruent sacroiliac joint(s) posteriorly. These injuries are associated with hollow viscus and solid organ injury and life-threatening hemorrhage. These injuries have a predilection for hemorrhage and may require significant transfusion of blood and blood products for resuscitation.

Combined mechanisms can occur.

- Increasing degrees of displacement in any direction are associated with greater risk of hemorrhage.
 - Anterior-posterior injuries with complete disruption of all sacroiliac ligaments represent an internal hemipelvectomy and have the greatest potential for hemorrhage.

Immediate pelvic stabilization (pelvic binders, sheets, external fixation, C-clamp) can control hemorrhage and reduce mortality. This is particularly true in an austere environment with limited blood replacement products and other treatment resources.

- **Treatment.**
 - Hemorrhage control.
 - ◆ When pelvic fractures cause hemorrhage, the bleeding occurs from three major sources: arterial, venous, and cancellous bone. More than 70% of the hemorrhage associated with blunt pelvic trauma causing pelvic fracture is venous, and may be controlled with maneuvers that reduce the pelvic volume and stabilize the pelvis.
 - ◆ Volume reduction/mechanical stabilization can be obtained by:
 - ◇ Tying a sheet or placing a binder around the pelvis at the level of the greater trochanters.
 - ◇ Manually reducing the pelvis and placing bean bags or sandbags at the level of the trochanters.

- ◇ Positioning the patient in lateral decubitus with the affected side down.
- ◇ Tying the ankles together in internal rotation provides additional volume reduction.

Pelvic binders or sheets are the most expeditious way to control hemorrhage and provide pain relief through pelvic stabilization and reduction of intrapelvic volume. External fixators can provide longer term stabilization, but are difficult to place and have a higher incidence of complications. Skin necrosis can occur with long-term application of pelvic binders and sheets.

The other nearly 30% are associated with an arterial source and often require procedural interventions, such as surgical packing and/or embolization.

- Angiography is a useful adjunct, but is not usually available in the deployed environment. When available, angiographic exploration with early embolization for the hemodynamically unstable patient with intrapelvic hemorrhage may be beneficial.
- Given that this capability is rarely available outside of a Role 3 facility, the next most beneficial maneuver is retroperitoneal packing via a suprapubic incision.
- Attempts at opening a retroperitoneal pelvic hematoma (as a result of a pelvic fracture) from inside the abdomen should be resisted at all costs and attempted only as a last resort.
- None of these interventions should delay the necessary acute surgical treatment for concomitant hemorrhagic injuries.
 - Open blunt injuries require:
 - ◆ Immediate hemorrhage control by packing.
 - ◆ Aggressive and thorough debridement.
 - ◆ Pelvic stabilization by external fixation.
 - ◆ Diverting colostomy in the presence of wounds at risk for fecal soilage.
 - Definitive internal pelvic stabilization (plates, screws, etc) is done outside of the combat zone.

Missile and fragmentation wounds can cause pelvic fractures.

- **The pelvis usually remains mechanically stable.**
- **The colon, small intestine, rectum, and the genitourinary tracts must all be assessed for associated injury.**
- **Major hemorrhage can result from injury to the iliac vessels.**

Penetrating Injuries

- **Evaluation.**
 - Diagnosis of associated injuries may require exploratory laparotomy.
 - Fractures should be assessed with radiographs and CT scans, when available, to rule out extension into the hip and acetabulum.
- **Treatment.**
 - Control hemorrhage and resuscitate with blood and blood products.
 - Control hollow viscus injury.
 - Thoroughly debride wounds and fractures.

For combined hollow viscus and acetabulum/hip joint injuries, the joint is contaminated and must be explored and treated as described in Chapter 9, Soft-Tissue and Open Joint Injuries.

- **Technique of sheet or pelvic binder application.**
 - Slide the folded sheet (30–40 cm wide) or binder under the supine patient, centered at the level of the greater trochanters.
 - With a second individual on the opposite side of the table, overlap the ends of the sheet (or Velcro straps of the binder) circumferentially, applying compression across the pelvis.
 - Secure the sheet in place with large Kelly clamps, or, alternatively, tighten the draw string on the binder.
 - Binders can be left in place for 24–48 hours, but require frequent skin checks for longer periods of use.
 - Confirm reduction of the pelvis with an anterior-posterior pelvis X-ray.

- **Technique of pelvic external fixator placement (Fig. 21-1).**
 - Prep the iliac crests.
 - Place a 2-cm horizontal incision over the iliac crest, 2–3 cm posterior to the anterior-superior iliac spine.

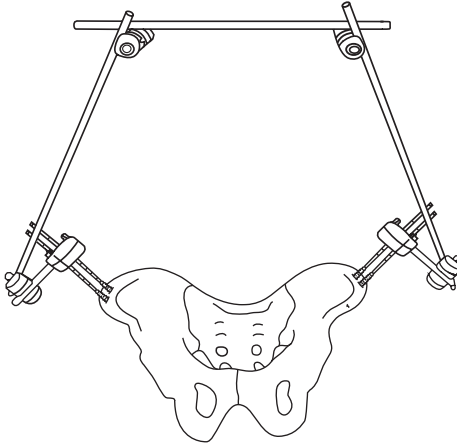


Fig. 21-1. Pelvic external fixator placement.

- Bluntly dissect to the iliac crest, taking care to identify the intermuscular plane between the external oblique and iliacus, which will lessen bleeding.
- To determine the angle of the pelvis, first slide a guide pin between the muscle and the bone along the inner table of the iliac wing no deeper than 3–4 cm.

Failure to properly determine the angle of the iliac wing leads to inadequate fixation and may cause significant complications.

- Locate the junction of the middle and medial thirds of the thickness of the iliac crest with the tip of a 5-mm external fixator pin.
- Paralleling the guide pin, begin drilling the pin into the crest.

- Drill between the inner and outer tables to a depth of about 4 cm, aiming generally toward the greater trochanter. Only gentle pressure should be applied once the pin threads have engaged to allow for the pin to guide itself between the tables.
- A second pin is inserted 1–2 cm more posteriorly on the crest.
- Check the stability of each pin. If unsatisfactory, attempt reinsertion by aiming between the tables.
- Place pins in the contralateral iliac crest in the same manner.
- Reduce the pelvis by applying pressure on the pelvis (**not the pins!**) and connect the external fixator pins with bar(s) across the abdomen and pelvis to maintain reduction.
- **Technique for retroperitoneal packing.**
 - Prep the abdomen and make an 8-cm midline incision extending proximally from the level of the symphysis pubis toward the umbilicus.
 - Divide the fascia of the rectus abdominus in its midline, taking care to avoid penetrating the underlying bladder.
 - Retract the bladder to one side with the use of a malleable retractor, and identify the pelvic brim beginning at the level of the symphysis pubis and extending posteriorly.
 - To the greatest extent possible, quickly identify whether the bulk of the bleeding encountered is venous or arterial in nature. If arterial, consider subsequent embolization procedures.
 - Taking care to avoid disruption of anomalous vascular connections between the obturator and iliac systems (corona mortis), identify the pelvic brim and place the first of three laparotomy sponges with the aid of a sponge stick posteriorly to the level of the sacroiliac joint, below the level of the pelvic brim (true pelvis).
 - A second sponge is packed at the midportion below the pelvic brim, with the third sponge placed below the bladder anteriorly into the space of Retzius.
 - The bladder is retracted to the other side, and the procedure is repeated for the opposite hemipelvis.
 - The rectus fascia is closed, with a single layer running suture and the skin closed with staples.

- Exploratory laparotomy, if required, should follow closure of the retroperitoneal fascia to allow for the continued tamponade of the vessels in the retroperitoneum.
- Packing should be carefully removed within 24–48 hours.
- **Technique of pelvic C-clamp placement (Fig. 21-2).**
(For markedly unstable injuries—ie, internal hemipelvectomy and shock unresponsive to fluid resuscitation.)
 - Extend a line along the axis of the femur curving proximally and posteriorly above the level of the greater trochanter, along the lateral aspect of the pelvis.
 - Extend a second line perpendicular to the floor at the level of the anterior-superior iliac spine so that it intersects the first line.



Fig. 21-2. Placement of a pelvic C-clamp. Intersection of lines indicates the correct entry point.

- Prep the area and make a 2-cm incision at the intersection of the two lines above. Dissect with a blunt instrument to the level of the pelvic groove formed by angulation of the lateral cortex of the iliac wing (at the margin between the true and false pelvis).
- Insert the first pin with the disengaged arm of the C-clamp to the groove on the uninjured side of the hemipelvis first and impact gently with a mallet.
- Engage the pin on the opposite injured side in a similar manner by sliding the arms of the clamp together. Further tightening of the threads can provide definitive compression of the posterior pelvic ring.

- o Confirm reduction with an anterior-posterior pelvis X-ray.

For Clinical Practice Guidelines, go to
[http://usaisr.amedd.army.mil/clinical_practice_
guidelines.html](http://usaisr.amedd.army.mil/clinical_practice_guidelines.html)

