

## Chapter 14

# Ocular Injuries

### Introduction

The preservation of the eyes and eyesight of service personnel is an extremely important goal. Despite comprising as little as 0.1% of the total body surface area, injuries to the eye have been sustained in 6% of all combat casualties in Operation Iraqi Freedom/Operation Enduring Freedom. In the Vietnam War, almost 50% of casualties with penetrating eye wounds eventually lost vision in the injured eye. Improvements in ophthalmic care in the last 30 years offer hope that blindness in combat casualties will be increasingly less common in future wars.

### Triage of Patients With Eye Injuries

- Advanced Trauma Life Support protocols: After primary survey is complete and the patient is stable, identify and treat ocular injuries in the secondary survey.
- Casualties with mild eye injuries may be treated and returned to duty.
- Casualties with more severe injuries should be evacuated to save vision.
- Distinguishing major ocular injuries from minor ones may be difficult.
- At Role 1/2, due to time and equipment restraints, medical personnel will likely “shield and evacuate.” If an open globe is suspected, cover the eye with a shield made with a device that applies forces to the bony orbit area instead of to the eye.

### Identifying Severe Eye Injuries

- Associated injuries.
  - Fragmentation wounds of the face—think intraocular foreign body.

- Lid laceration—open the eyelids and check for underlying globe laceration.
- Vision.
  - Use book print, medication labels, finger counting, etc, to evaluate vision.
  - Compare sight in the injured eye to the uninjured eye.
  - Severe vision loss is a strong indicator of serious injury.
- Eyeball structure.
  - Obvious corneal or scleral lacerations.
  - Subconjunctival hemorrhage (SCH)—may overlay an open globe.
  - Dark uveal tissue presenting on the surface of the eye indicates an open globe.
  - Foreign body—did it penetrate the eye?
  - Blood in the anterior chamber (hyphema) indicates severe blunt trauma or penetrating trauma.
- Proptosis—may indicate a retrobulbar hemorrhage, which is an ocular emergency.
- Pupils.
  - Pupillary distortion—may be associated with an open globe.
- Motility.
  - Decreased motility on one side may be caused by an open globe.
  - Other causes include muscle injury, orbital fracture, and orbital hemorrhage.

### **Open Globe**

- May result from penetrating or blunt eye trauma.
- May cause loss of vision from either disruption of ocular structures or secondary infection (endophthalmitis).
- Biplanar radiographs or a CT scan of the head may help to identify a metallic intraocular fragment in a casualty with severe vision loss, a traumatic hyphema, a large SCH, or other signs suspicious for an open globe with an intraocular foreign body. Fine orbit cuts at every 1 mm are required to properly view the globe. Routine head 4-mm CT cuts may miss a high number of globe metallic foreign bodies or injuries.

### **Immediate Treatment of an Open Globe**

- Tape a rigid eye shield (NOT a pressure patch) over the eye.
- Do not apply pressure on or manipulate the eye, including ultrasound.
- Apply shield to opposite eye to limit motion of injured eye.
- Do not apply any topical medications.
- Start quinolone antibiotic PO or IV (eg, Levoquinone 500 mg qd).
- Schedule an urgent (within 24–48 hours) referral to an ophthalmologist with surgical capabilities.
- Administer tetanus toxoid if indicated.
- Prevent emesis (Phenergan 50 mg or Compazine 10 mg IM/IV).

### **Treatment of Other Anterior Segment Injuries**

#### **Subconjunctival Hemorrhage**

- Small SCHs may occur spontaneously or in association with blunt trauma. These lesions require no treatment.
- SCHs may also occur in association with a rupture of the underlying sclera.
- Warning signs for an open globe include a large SCH with chemosis (conjunctiva bulging away from the globe) in the setting of blunt trauma, or **any** SCH in the setting of penetrating injury. Casualties with blast injury and normal vision do not require special care.
- Suspected open globe patients should be treated as described previously.

#### **Treatment of Chemical Injuries of the Cornea**

- Nonsterile water may be used if it is the only liquid available.
- Use topical anesthesia before irrigating, if available (tetracaine or proparacaine ophthalmic).
- Measure the pH of tears to ensure that, if there is either acid or alkali in the eye, the irrigation continues until the pH returns to normal. Do not use alkaline solutions to neutralize acidity or vice versa.
- Remove any retained particles.
- Using the fluorescein test, look for epithelial defect (ie, corneal abrasions):

- If none, then mild chemical injuries or foreign bodies may be treated with artificial tears.
- If an epithelial defect is present, use a broad-spectrum antibiotic ophthalmic ointment (Polysporin, erythromycin, or Bacitracin) 4 times per day.
- Noncaustic chemical injuries usually resolve without sequelae.
- More severe chemical injuries require ophthalmological evaluation.
- Monitor (daily topical fluorescein evaluation) for a corneal ulcer until epithelial healing is complete.
- Severe acid or alkali injuries of the eye (recognized by pronounced chemosis, limbal blanching, and/or corneal opacification) can lead to infection of the cornea, glaucoma, and possible loss of the eye. Refer to an ophthalmologist within 24–48 hours.
- Treat mustard eye injuries with ophthalmic ointments, such as 5% boric acid ointment, to provide lubrication and minimal antibacterial effects. Apply sterile petrolatum jelly between the eyelids to provide additional lubrication and prevent sealing of the eyelids.
- Treat nerve agent ocular symptoms with 1% atropine sulfate ophthalmic ointment; repeat as needed at intervals of several hours for 1–3 days.

### **Corneal Abrasions**

- Diagnosis.
  - Be alert for the possibility of an associated open globe.
  - The eye is usually very symptomatic, with pain, tearing, and photophobia.
  - Vision may be diminished from the abrasion itself or from the profuse tearing.
  - Diagnose with topical fluorescein and cobalt blue light (Wood's lamp).
  - A topical anesthetic as above may be used for diagnosis, but should NOT be used as an ongoing analgesic agent—this delays healing and may cause other complications.
- Treatment.
  - Apply broad-spectrum antibiotic ointment (Polysporin, erythromycin, or Bacitracin) qid.

- Options for pain relief.
  - ◆ Diclofenac: 0.1% drops qid.
  - ◆ Larger abrasions may require a mild cycloplegic agent (1% Mydrilac or Cyclogyl).
  - ◆ More severe discomfort can be treated with 0.25% Scopolamine 1 drop bid, but this will result in pupil dilation and blurred vision for 5–6 days.
- Small abrasions usually heal well.
- If the eye is not shielded:
  - ◆ Antibiotic drops (fluoroquinolone or aminoglycoside) may be used qid in lieu of ointment.
  - ◆ Sunglasses are helpful in reducing photophobia.
- Casualties who wear contact lenses should have the lens removed and not be reinserted until symptom-free and normal eye exam.
- Abrasions will normally heal in 1–4 days.
- Initial treatment of thermal burns of the cornea is similar to that for corneal abrasions.

**All corneal abrasions need to be checked once a day until healing is complete to ensure that the abrasion has not been complicated by secondary infection (corneal ulcer, bacterial keratitis).**

### **Corneal Ulcer and Bacterial Keratitis**

- **Diagnosis.**
  - **Corneal ulcer and bacterial keratitis are serious conditions that may cause loss of vision or even loss of the eye!**
  - A history of corneal abrasion or contact lens wear.
  - Increasing pain and redness.
  - Decreasing vision.
  - Persistent or increasing epithelial defect (positive fluorescein test).
  - White or gray spot on the cornea seen on examination with a penlight or direct ophthalmoscope.
- **Treatment.**
  - Quinolone drops (eg, Ocuflax), 1 drop every 5 minutes for 5 doses initially, then 1 drop every 30 minutes for 6 hours, and then 1 drop hourly around the clock thereafter.

- Scopolamine 0.25%, 1 drop bid, may help relieve discomfort caused by ciliary spasm.
- Patching and use of topical anesthetics for pain control are contraindicated (see pain control measures discussed previously).
- Expedited referral to an ophthalmologist within 3–5 days, sooner if ocular injury is deteriorating. Infection may worsen, leading to permanent injury.

### **Conjunctival and Corneal Foreign Bodies**

- **Diagnosis.**
  - Abrupt onset of discomfort and/or history of suspected foreign body.
  - If an open globe is suspected, treat as discussed previously.
  - Definitive diagnosis requires visualization of the offending object, which may sometimes be quite difficult.
    - ◆ A hand-held magnifying lens or pair of reading glasses will provide magnification to aid in the visualization of the foreign body.
    - ◆ Stain the eye with fluorescein to check for a corneal abrasion.
  - The casualty may be able to help with localization if asked to indicate the perceived location of the foreign body prior to instillation of topical anesthesia.
  - Eyelid eversion with a cotton-tipped applicator helps the examiner identify foreign bodies located on the upper tarsal plate.
- **Treatment.**
  - Superficial conjunctival or corneal foreign bodies may be irrigated away or removed with a moistened sterile swab under topical anesthesia.
  - Objects adherent to the cornea may be removed with a swab or a sterile 22-gauge hypodermic needle mounted on a tuberculin syringe (hold the needle **tangential** to the eye).
  - If no foreign body is visualized, but the index of suspicion is high, vigorous irrigation with artificial tears or sweeps of the conjunctival fornices with a moistened cotton-tipped applicator after topical anesthesia may be successful in removing the foreign body.

- If an epithelial defect is present after removal of the foreign body, treat as discussed previously for a corneal abrasion.

### **HypHEMA: Blood in the Anterior Chamber**

- Treatment (to prevent vision loss from increased intraocular pressure):
  - Be alert for a possible open globe and treat for that condition if suspected.
  - Avoidance of rebleeds is a major goal of management.
    - ◆ **Avoid** aspirin or nonsteroidal antiinflammatory drugs.
    - ◆ No strenuous activity (bedrest with head of bed elevated) for 7 days.
    - ◆ No reading for 7 days to minimize rapid eye movements.
  - Prednisolone 1%—1 drop 4 times a day.
  - Scopolamine 0.25%—1 drop twice a day.
  - Cover eye with protective shield.
  - Elevate head of bed to promote settling of red blood cells in anterior chamber.
  - Provide a 24- to 48-hour referral to an ophthalmologist to monitor for increased intraocular pressure (which may cause permanent injury to the optic nerve) and to evaluate for an associated open globe.
  - If evaluation by an ophthalmologist is delayed (>24 hours), treat with a topical beta-blocker (Timolol or Levobunolol) bid to help prevent intraocular pressure elevation.
  - If intraocular pressure is found to be markedly elevated (above 30 mm Hg) with a tonopen or other portable tonometry device, other options for lowering intraocular pressure include acetazolamide 500 mg PO or IV and mannitol 1–2 g/kg IV over 45 minutes.

### **Retrobulbar (Orbital) Hemorrhage**

- Keys to recognition: Severe eye pain, proptosis, vision loss, and decreased eye movement.
  - Marked lid edema may make the proptosis difficult to appreciate. Inability to open the lids, even with cotton swabs, is highly suspicious for this.
  - Failure to recognize may result in blindness from increased ocular pressure.
- Perform an immediate lateral canthotomy and cantholysis.

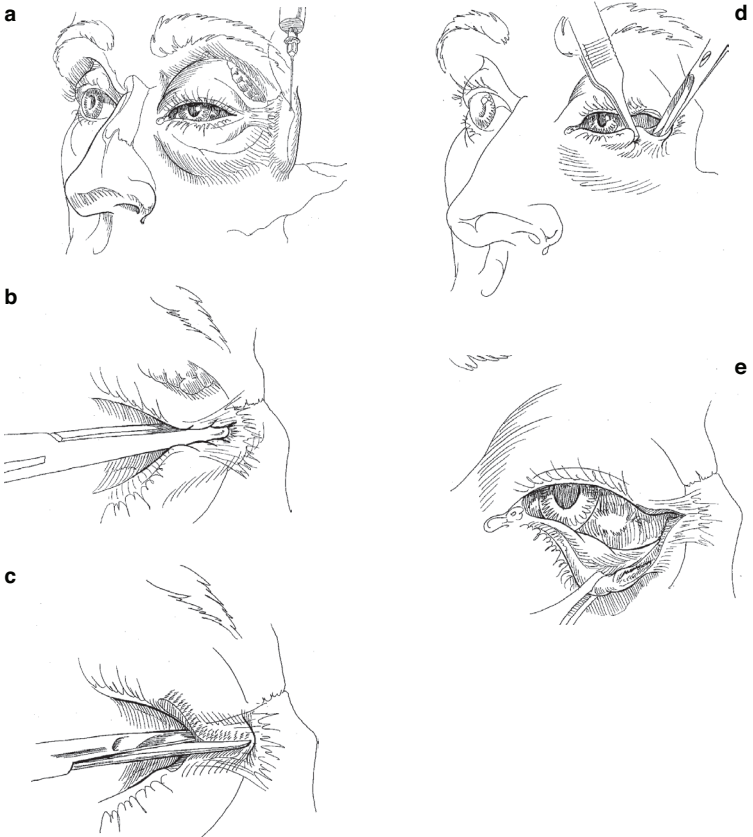
- Provide an urgent referral to an ophthalmologist, within 24–48 hours.
- If evaluation by an ophthalmologist is delayed (>24 hours), treat with a topical beta-blocker (Timolol) bid to help lower intraocular pressure elevation.
- If intraocular pressure is found to be elevated (>30 mm Hg), treat as discussed previously.

### **Lateral Canthotomy/Cantholysis**

The indication for lateral canthotomy/cantholysis is orbital compartment syndrome. Do not perform such procedures if the eyeball structure has been violated. If there is a penetrating globe injury, apply a Fox shield for protection and seek immediate ophthalmic surgical support.

- Inject 2% lidocaine with 1:100,000 epinephrine into the lateral canthus (Fig. 14-1a).
- Crush the lateral canthus with a straight hemostat, advancing the jaws to the lateral fornix (Fig. 14-1b).
- Using straight scissors, make a 1-cm-long horizontal incision of the lateral canthal tendon, in the middle of the crush mark (Fig. 14-1c).
- Grasp the lower eyelid with large toothed forceps, pulling the eyelid away from the face. This pulls the inferior crus (band of the lateral canthal tendon) tight so it can be easily cut loose from the orbital rim (Fig. 14-1d). It will have a “banjo string” feel against the tip of the scissors.
  - Use blunt-tipped scissors to cut the inferior crus.
  - Keep the scissors parallel (flat) to the face with the tips pointing toward the chin.
  - Place the inner blade just anterior to the conjunctiva and the outer blade just deep to the skin.
  - The eyelid should pull freely away from the face, releasing pressure on the globe. (Fig. 14-1e)
  - Cut residual lateral attachments of the lower eyelid if it does not move freely.
  - Do not worry about cutting ½ cm of conjunctiva or skin.
  - The lower eyelid is cut, relieving orbital pressure. If the intact cornea is exposed, apply, hourly, copious erythromycin ophthalmic ointment or ophthalmic lubricant ointment to prevent devastating corneal desiccation and infection. Relief





**Fig. 14-1.** Lateral canthotomy and inferior cantholysis are indicated for casualties presenting with serious orbital hemorrhage.

of orbital pressure must be followed by lubricating protection of the cornea and urgent ophthalmic surgical support. Do NOT apply absorbent gauze dressings to the exposed cornea.

### **Orbital Floor (Blowout) Fractures**

These fractures are usually the result of a blunt injury to the globe or orbital rim, often associated with head and spine injuries. Blowout fractures may be suspected on the basis of enophthalmos, diplopia, decreased ocular motility, hypoesthesia of the V2 branch of the trigeminal nerve, associated SCH, or

hyphema. Immediate treatment includes pseudoephedrine 60 mg q6h and a broad-spectrum antibiotic for 7 days, ice packs, and instructing the casualty not to blow his/her nose. Definitive diagnosis requires CT scan of orbits with axial and coronal views. Indications for repair include severe enophthalmos and diplopia in the primary or reading gaze positions. Not an urgent matter, surgery may be performed 1–2 weeks after the injury.

### **Lid Lacerations**

#### **Treatment Guidelines for Lid Lacerations Not Involving the Lid Margin**

- Excellent blood supply—delayed primary closure is not necessary.
- Eyelid function (protecting the globe) is the primary consideration.
- Begin with irrigation, antisepsis (any topical solution), and a check for retained foreign bodies.
- Superficial lacerations of the eyelid, not involving the eyelid margin, may be closed with running or interrupted 6-0 silk or monofilament.
- Horizontal lacerations should include the orbicular muscle and skin in the repair.
- If skin is missing, an advancement flap may be created to fill in the defect. For vertical or stellate lacerations, use traction sutures in the eyelid margin for 7–10 days.
- Antibiotic ointments qid.
- Skin sutures may be removed in 5 days.

#### **Treatment Guidelines for Lid Lacerations Involving the Lid Margin**

- Repair of a marginal lower eyelid laceration with <25% tissue loss (Fig. 14-2a).
  - The irregular laceration edges may be freshened by creating a pentagonal wedge; remove as little tissue as possible (Fig. 14-2b).
  - A 4-0 silk or nylon suture is placed in the eyelid margin (through the meibomian gland orifices 2 mm from the wound edges and 2 mm deep) and is tied in a slipknot. Symmetric suture placement is critical to obtain post-op eyelid margin alignment (Fig. 14-2c).

- o The slipknot is loosened, and approximately 2 or 3 absorbable (VICRYL or gut) 5-0 or 6-0 sutures are placed internally to approximate the tarsal plate. The skin and conjunctiva should not be included in this internal closure (Figs. 14-2g and 14-2h).

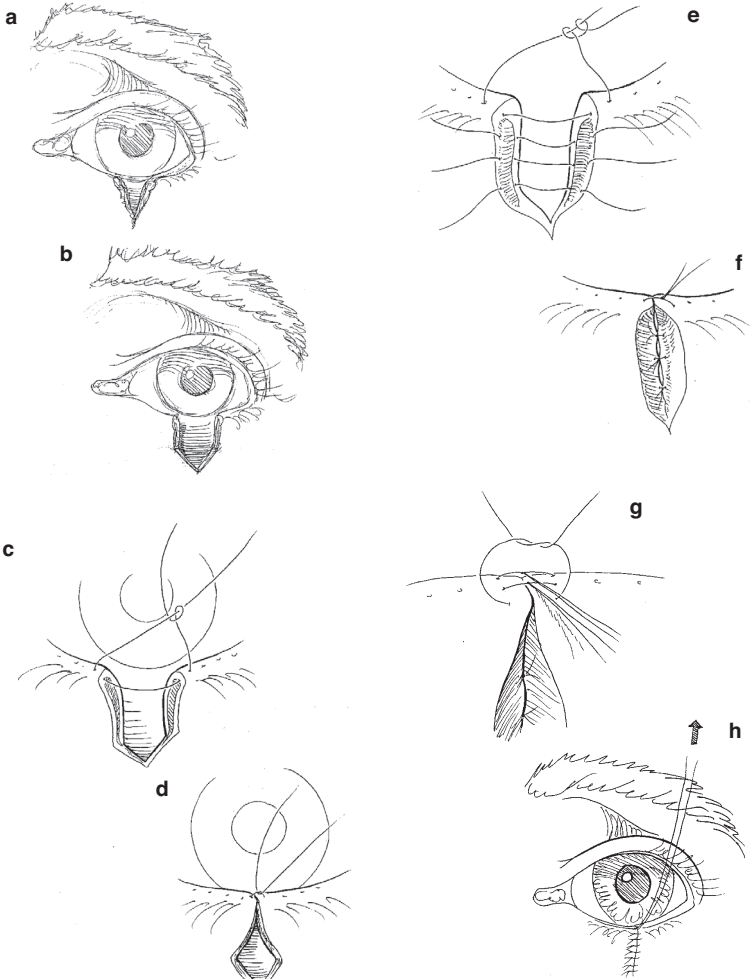


Fig. 14-2. Lid margin repair.

- Anterior and posterior marginal sutures (6-0 silk or nylon) are placed in the eyelid margin just in front and behind the previously placed 4-0 suture (Fig. 14-2e).
- The middle and posterior sutures are left long and tied under the anterior suture. Ensure that the wound edges are everted (Fig. 14-2f).
- Skin is closed with 6-0 silk or nylon sutures. The lid is placed on traction for at least 5 days. Skin sutures are removed in 3–5 days, and the marginal sutures are removed in 10–14 days (Figs. 14-2g and 14-2h).

### **Additional Points in Lid Laceration Repair**

- Tissue loss >25% will require a flap or graft. Best managed by eye surgeon.
- If there is orbital fat in the wound or if ptosis is noted in an upper lid laceration, damage to the orbital septum and the levator aponeurosis should be suspected.
- If the eyelid is avulsed, the missing tissue should be retrieved, wrapped in moistened Telfa, and preserved on ice. The tissue should be soaked in a diluted antibiotic solution prior to reattachment. If necrosis is present, minimal debridement should occur to prevent further tissue loss. The avulsed tissue should be secured in the anatomically correct position in the manner described for lid margin repair as described previously.
  - Damage to the canalicular system can occur as a result of injuries to the medial aspect of the lid margins. Suspected canalicular injuries should be repaired by an ophthalmologist to prevent subsequent problems with tear drainage. This repair can be delayed for up to 24 hours.

### **Laser Eye Injuries**

- Battlefield lasers may be designed to cause eye injuries or may be part of other weapons or sensor systems.
- **Prevention is the best option!** Wear eye protection designed for the appropriate light wavelengths if there is a known laser threat.
- The type of ocular damage depends on the wavelength of the laser. Retinal injuries are most common.

- The primary symptom of laser injury is loss of vision, which may be preceded by seeing a flash of light. Pain may not be present.
- Immediate treatment of corneal laser burns is similar to that for corneal abrasions.
- Laser retinal burns have no proven immediate treatment, although improvement with corticosteroids has been reported.
- Routine evacuation for evaluation by an ophthalmologist is required.

### **Enucleation**

A general surgeon in a forward unit should not remove a traumatized eye unless the globe is completely disorganized. Enucleation should only be considered if the patient has a very severe injury, no light perception using the brightest light source available, and is not able to be evacuated to a facility with an ophthalmologist. Sympathetic ophthalmia is a condition that may result in loss of vision in the fellow eye if a severely traumatized, nonseeing eye is not removed; however, it rarely develops prior to 21 days after an injury. **Thus, delaying enucleation until the patient is in the care of an ophthalmologist is relatively safe.**

For Clinical Practice Guidelines, go to  
[http://usaisr.amedd.army.mil/clinical\\_practice\\_guidelines.html](http://usaisr.amedd.army.mil/clinical_practice_guidelines.html)

